

|||||  
**Case Report**  
|||||

## Hemolytic Anemia soon after Replacement of Ascending Aorta for acute Aortic Dissection

Ikuko Shibasaki, MD, PhD, Hirotsugu Fukuda, MD, PhD, Yasuyuki Yamada, MD, PhD, Toshiyuki Kuwata, MD, Hironaga Ogawa, MD, Go Tsuchiya, MD, Takayuki Hori, MD, Yusuke Takei, MD, Takashi Kato, MD

*Department of Cardiac and Vascular Surgery, Dokkyo Medical University School of Medicine*

### SUMMARY

A 61-year-old female underwent replacement of the ascending aorta for Type A aortic dissection, then gradually developed severe hemolytic anemia over 1 month. The cause of hemolysis was found to be mechanical damage of red blood cells caused by an inverted felt strip at the proximal anastomosis. A reoperation for resection of the felt and repair of the proximal anastomosis successfully resolved the problem. Here, we report a rare case of hemolytic anemia at the site of an inverted felt strip that occurred after replacement of the ascending aorta.

**Key Words** : replacement of ascending aorta, Hemolytic anemia, Teflon felt strip

### INTRODUCTION

Despite recent advances in surgical techniques and perioperative care, acute type A aortic dissection (AAD) remains a life-threatening disease with an in-hospital mortality rate ranging from 15–30%<sup>1,2)</sup>. Various reports have noted postoperative complications associated with AAD, with hemolysis related to a kinked prosthetic graft<sup>3)</sup> or jet of blood striking an inner felt strip<sup>4–7)</sup>. We report a case of hemolytic anemia caused by the inverted felt strip at the site after surgical treatment for aortic dissection using felt strips.

### CASE

The patient was a 61-year-old woman, who visited

our hospital because of sudden chest and back pain. She was diagnosed with a Type A intramural hematoma from an AAD based on CT scanning findings and was hospitalized for conservative medical treatment. The next day, she complained of chest pain and was diagnosed with a Type A AAD based from CT scan images. The patient subsequently underwent emergency ascending aorta replacement.

### FIRST SURGERY

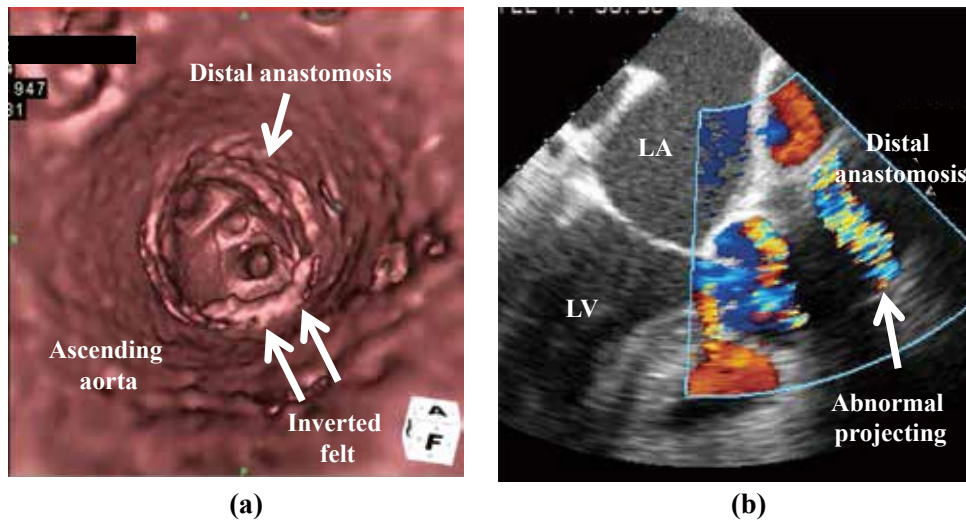
The operation was performed through a median sternotomy. Cardiopulmonary bypass (CPB) was established with standard retrograde perfusion through the femoral artery, with perfusion also used for maintaining true channel circulation and an easy shift to selective antegrade cerebral perfusion (SCP). The patient was cooled to approximately 28°C. Under hypothermic circulatory arrest, the ascending aorta was opened without an aortic clamp, and a SCP balloon-tipped cannula was inserted into the right innominate artery, left common carotid artery, and left subclavian artery. An intimal tear was found located in the ascending aorta.

---

Received August 7, 2014 ; accepted September 4, 2014

Reprint requests to : Ikuko Shibasaki, MD, PhD

Department of Cardiac and Vascular Surgery,  
Dokkyo Medical University School of Medicine,  
880 Kitakobayashi, Mibu, Tochigi, 321-0293,  
Japan



**Figure 1** Images of an anastomotic site of ascending aortic replacement.

- (a) : CT scan demonstrate an inner felt projected out into the aortic lumen at the distal anastomosis.  
 (b) : TEE image demonstrate an abnormal projection into the aortic lumen at the distal anastomosis.

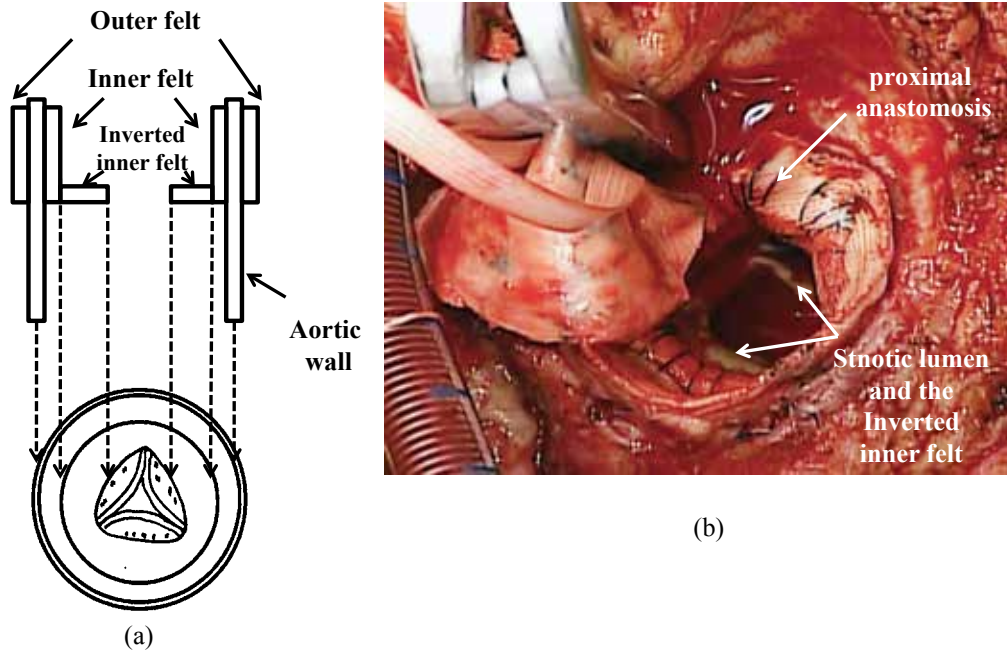
The distal site of the dissected aorta was reconstructed with Gelatin-resorcin-formal (GRF) glue and the wall of the aorta was sutured with Prolene (5-0). In addition, we reinforced the mattress sutures with inner and outer teflon felt strips in the same manner as described above for the proximal site. Replacement of the ascending aorta was done using a 26-mm Dacron graft (Vascutek® Gelseal™, Terumo Cardiovascular Systems Co., Ann Arbor, MI, USA).

Postoperative CT scans showed no residual dissection in the thoracic and abdominal aorta. However, 1 month later, a systolic ejection murmur of Levine II/VI was noted at the left sternal border of the second intercostal space as well as dark brown urine. CT scanning showed no signs of anastomotic stenosis or graft kinking, while an inner felt was observed projecting into the aortic lumen at the distal anastomosis (Fig 1). Transesophageal echocardiography (TEE) showed no asynergy, though the abnormal projection into the aortic lumen at the distal anastomosis caused blood to jet toward the reversed inner felt strips (Fig 1). Hemoglobin (Hb), lactate dehydrogenase (LDH), and total bilirubin (T-bil) levels 7.4 g/dl, 1893 IU/L and 2.6 mg/dl, respectively. An examination of peripheral blood showed a number of fragmented red blood cells. Our diagnosis was hemolytic anemia and conservative med-

ical therapy was provided for 2 weeks with sargoprelate,  $\beta$ -blocker, and human haptoglobin. However, the hemolytic anemia did not improve, and a reoperation was necessary, as the patient required a transfusion.

## REOPERATION

Finally, Re-operation was performed two months after first operation. Before re-performing a median sternotomy, the right axillary artery was taped. CPB was established with arterial cannulation from the branch of the previous graft at the ascending aorta, and venous cannulation from the superior vena cava (SVC) and inferior vena cava (IVC). Thrilling was detected from the proximal anastomosis. Aortic cross clamping was performed just prior to distal anastomosis when rectal temperature reached 28°C. When the graft was opened, we noted that the proximal anastomosis had developed stenosis because of inversion of the inner felt, which reduced the size of the internal lumen (Fig 2). We attributed hemolysis to the collision or acceleration of blood flow at the level of the inverted felt strip, which was resected. Declamping was performed under circulatory arrest within a few minutes and retrograde cerebral perfusion was established with the SVC. The distal anastomosis showed no evidence of stenosis and



**Figure 2** Schematic illustration and operative finding.

- (a) : Intraoperative finding of the proximal anastomosis. the outer felt was intact and the inner felt had been inverted.
- (b) : Intraoperative finding shows stenotic aortic lumen caused by the circumferentially inverted internal felt strip.

we directly sutured the graft. Weaning from CPB was relatively smooth and no thrilling was detected from the proximal anastomosis. CPB time was 160 minutes, while aortic cross clamp time was 47 minutes. The patient showed a good postoperative course and was extubated on the same day as the operation. Hb, LDH, and T-bil levels were 11.8 g/dl, 265 IU/L and, 0.8 mg/dl, respectively, and she was discharged on postoperative day 8. At a check-up examination 4 years later, no recurrence was observed.

## DISCUSSION

Hemolytic anemia frequently develops after prosthetic valve replacement and a mitral valve plasty. However, it is a rare complication in cases with AAD. In this case report, we presented a rare case of hemolytic anemia at the site of inverted felt strip after ascending aorta replacement. Several causes have been reported, a kinked prosthetic graft<sup>3)</sup>, a pseudoaneurysm pressed the anastomosis<sup>8)</sup>, and jet of blood striking an inner felt strip<sup>4~7)</sup>. A Teflon felt strip has been widely used for anastomotic reinforcement in cardiovascular surgery, but it reported to cause complica-

tions such as infection and embolization<sup>10,11)</sup>. The mechanism of hemolysis caused by use of Teflon felt strip is considered to be related to the inner felt at the proximal anastomosis that inverts to cause a jet of blood stream, which destroys red blood cells. In similar reports,<sup>4~7)</sup> the time period for development of hemolytic anemia varied from 1 to 6 years and hemolysis was shown to originate from the proximal anastomosis. In addition to hemolytic anemia, cardiac failure due to felt stenosis or infection has been reported<sup>6~8)</sup>.

During an operative procedure for AAD, the site of anastomosis techniques in repair can be problematic. Especially in cases of AAD, complications such as hemorrhage and pseudoaneurysm at the site of anastomosis and residual dissection including tissue at the site make the condition fragile. Generally, this is a technique for anastomosis with GRF glue is employed in the false lumen, with the inner and outer sides of the cut end reinforced with Teflon felt. For preventing these, this technique is performed to reinforce the anastomosis. The adventitial inversion<sup>9,10)</sup> and fabric neomedia<sup>11)</sup> techniques have also been reported. Soon after becoming available, the usefulness of GRF glue

for closing a dissection lumen was frequently reported<sup>12,13</sup>. However, some have reported<sup>14,15</sup> that a pseudoaneurysm developed at the site of anastomosis after those procedures over longer terms.

The adventitial inversion technique is a type of amputation stump plasty that uses only autologous tissue, and does not utilize GRF glue or Teflon felt. Floten<sup>9</sup> reported favorable results with this technique, while another report noted an ingenious attempt at anastomosis by applying the felt on the inner side for avoiding complications such as embolization<sup>10</sup>. In a study of a fabric neomedia technique, it was also reported that fabric inserted to the Valsalva antrum might have a function to inhibit expansion of dissection-weakened tissue<sup>11</sup>.

In past reports<sup>4-7</sup>, CT (including 3-D CT), MRI, and TEE were performed for investigating the cause of hemolytic anemia in cases of acute aortic dissection. In our case, we were unable to make a diagnosis of hemolytic anemia caused by felt strip application, even though we performed preoperative CT and TEE.

In our case, Amputation stump plasty is our preferred method in this situation. When the previous graft was opened, the inner felt strip was found to be inverted by about 5 mm in the whole circumference, causing anastomotic stenosis. It was thought that it was caused by the fact that suture lines of a certain inside felt usually sewed up the upper part more. Based on this experience with the present case, for preventing felt stenosis, a mattress suture is placed close to the lower end of the felt so as not to reverse the felt end. Furthermore, a reinforced sizer was used at the time of ligation so as to avoid narrowing the lumen, resulting in a purse-string suture. Thereafter, similar complications have not been observed. In our patient, cardiac failure and infection caused by stenosis were not found prior to surgery. We were unable to make a diagnosis before surgery only on the basis of hemolytic anemia, which caused a delay until the reoperation. As for the surgical technique, sufficient care is required to decide the suturing position when reinforcing the felt during amputation stump plasty, as the graft bends easily, especially at the proximal anastomosis.

## CONCLUSION

We successfully performed a reoperation in a rare case with hemolytic anemia at the site of an inverted felt strip that developed after ascending aorta replacement for AAD. It is important to be aware of the possibility of hemolysis at the site of anastomosis in cases treated with felt strips.

## Conflict of interest

The authors declare that they have no conflict of interest.

## REFERENCES

- 1) Trimarchi S, Nienaber CA, Rampoldi V, et al : Contemporary results of surgery in acute type A aortic dissection : the International Registry of Acute Aortic Dissection experience. *J Thorac Cardiovasc Surg* **129** : 112-122, 2005.
- 2) Bachet J, Goudot B, Dreyfus GD, et al : Surgery for acute type A aortic dissection : The Hospital Foch experience (1977~1998). *Ann Thorac Surg* **67** : 2006-2009, 1999.
- 3) Koide S, Kanebuchib K, Suzuki I, et al. Studies of hemolysis after the ringed intraluminal graft surgery in the treatment of aortic dissection—Comparison with a case of hemolytic anemia from the kinked graft. *Jpn. J. Artif. Organs* **18** : 196-199, 1989.
- 4) Izumi S, Tano K, Horike K, et al : Repeat surgery for hemolysis 6 years after replacement of the ascending aorta for acute aortic dissection. *Jpn J Thorac Cardiovasc Surg* **51** : 459-461, 2003.
- 5) Shingu Y, Aoki H, Ebuoka N, et al : A surgical case for hemolytic anemia after ascending and total arch replacement. *Ann Thorac Cardiovasc Surg* **11** : 416-418, 2005.
- 6) Matsuura K, Ogino H, Minatoya K, et al : Aortic stenosis caused by the felt strip used in repair for acute aortic dissection. *Interact Cardiovasc Thorac Surg* **3** : 41-43, 2004.
- 7) Tomiyama T, Hosokawa Y, Imura H, et al : Haemolytic anaemia due to stenosed double-reinforced grafts after surgical repaired aortic dissection. *Interact Cardiovasc Thorac Surg* **15** : 525-527, 2012.
- 8) Sayar H, Dietl CA, Helms A, et al : Fragmentation hemolytic anemia 8 years after replacement of ascend-

- ing aorta with a sutureless intraluminal graft. *Am J Hematol* **81** : 175-177, 2006.
- 9) Floten HS, Ravichandran PS, Furnary AP, et al : Adventitial inversion technique in repair of aortic dissection. *Ann Thorac Surg* **59** : 771-772, 1995.
  - 10) Rylski B, Siepe M, Blanke P, et al : Adventitial inversion with graft telescopic insertion for distal anastomosis in acute type A aortic dissection. *Ann Thorac Cardiovasc Surg* **18** : 278-280, 2012.
  - 11) Nakajima T, Kawazoe K, Kataoka T, et al : Midterm results of aortic repair using a fabric neomedia and fibrin glue for type A acute aortic dissection. *Ann Thorac Surg* **83** : 1615-1620, 2007.
  - 12) Guilmet D, Bachet J, Goudot B, et al : Use of biological glue in acute aortic dissection. Preliminary clinical results with a new surgical technique. *J Thorac Cardiovasc Surg* **77** : 516-521, 1979.
  - 13) Hata H, Takano H, Matsumiya G, et al : Late complications of gelatin-resorcin-formalin glue in the repair of acute type A aortic dissection. *Ann Thorac Surg* **83** : 1621-1626, 2007.
  - 14) Bachet J, Goudot B, Teodori G, et al : Surgery of type A acute aortic dissection with gelatin-resorcine-formol biological glue : a twelve-year experience. *J Cardiovasc Surg* **31** : 263-273, 1990.
  - 15) Kamada T, Nakajima T, Izumoto H, et al : Late complications following surgery for type A acute aortic dissection using gelatin-resorcin-formaldehyde glue : report of two cases. *Surg Today* **35** : 996-999, 2005.