

Other

## Modified Bentall operation with bioprosthetic valve and Valsalva graft conduit : the “slit skirt” technique

Yasuyuki Yamada, MD, PhD<sup>1</sup>, Hirotsugu Fukuda, MD, PhD<sup>1</sup>, Ikuko Shibasaki, MD, PhD<sup>1</sup>,  
Yasushi Matsushita MD, PhD<sup>2</sup>, Koji Ogata MD, PhD<sup>1</sup>, Yuho Inoue, MD, PhD<sup>1</sup>,  
Shigeyoshi Gon, MD, PhD<sup>3</sup>, Toshiyuki Kuwata, MD<sup>1</sup>, Takayuki Hori, MD<sup>1</sup>,  
Go Tsuchiya, MD<sup>1</sup>, Hironaga, Ogawa, MD<sup>1</sup>, Yusuke Takei, MD<sup>1</sup>, Riha Shimizu, MD<sup>2</sup>,  
Masahiro Seki, MD<sup>1</sup>, Yuriko Kiriya, MD<sup>1</sup>, Takashi Kato, MD<sup>1</sup>, Yuta Kanazawa, MD<sup>1</sup>

<sup>1</sup>Department of Cardiac and Vascular Surgery, Dokkyo Medical University Heart Center, Tochigi, Japan

<sup>2</sup>Department of Cardiac and Vascular Surgery, Dokkyo Medical University Nikko Medical Center, Tochigi, Japan

<sup>3</sup>Department of Cardiovascular Surgery, Dokkyo Medical University Koshigaya Hospital, Saitama, Japan

### SUMMARY

We elucidated the efficacy of the slit skirt technique to prevent bleeding from the proximal anastomosis between the graft and aortic annulus. Between September 2008 and September 2014, 15 patients underwent a modified Bentall operation with the slit skirt technique at our institution. No patients had bleeding from the proximal anastomosis. No re-thoracotomy for bleeding was required. During midterm follow-up (median period, 21 months), no patient had pseudoaneurysms at the proximal suture line. We conclude that the slit skirt technique is useful to prevent bleeding from the proximal anastomosis after the Bentall operation.

**Key Words** : Bentall operation, Proximal anastomosis, Composite graft

### INTRODUCTION

The Bentall operation with a composite graft for aortic root replacement is associated with a risk of bleeding from the proximal anastomosis. The use of a bioprosthetic valve is becoming more common in the surgical management of aortic valve disease. Commercially available composite graft have been historically constructed with a mechanical valve, but more recently there have been biological composite graft available

on the market. However, a bioprosthetic valve conduit was not yet commercially available in Japan until 2014. Many modifications of the sewing technique to reinforce the proximal anastomosis have been reported<sup>1,2)</sup>. We elucidated the efficacy of the modified Bentall operation using a bioprosthetic valve and Valsalva graft conduit to prevent bleeding from the proximal anastomosis between the graft and aortic annulus.

### TECHNIQUE


A median sternotomy approach was used in all cases. Cardiopulmonary bypass was established with distal ascending aorta or aortic arch and axillary arterial and right atrium cannulation. On full cardiopulmonary bypass with normothermia, an aortic cross clamp was placed, and cardiac asystole was obtained in a standard fashion using antegrade and retrograde cardioplegia

---

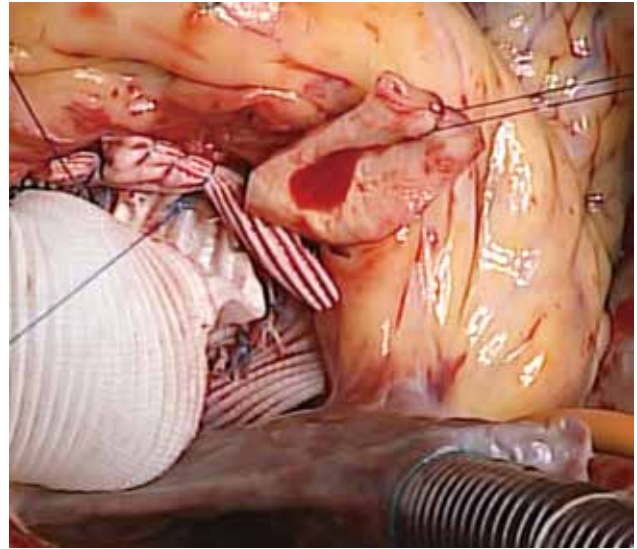
Received June 17, 2015 ; accepted September 8, 2015

Reprint requests to : Yasuyuki Yamada

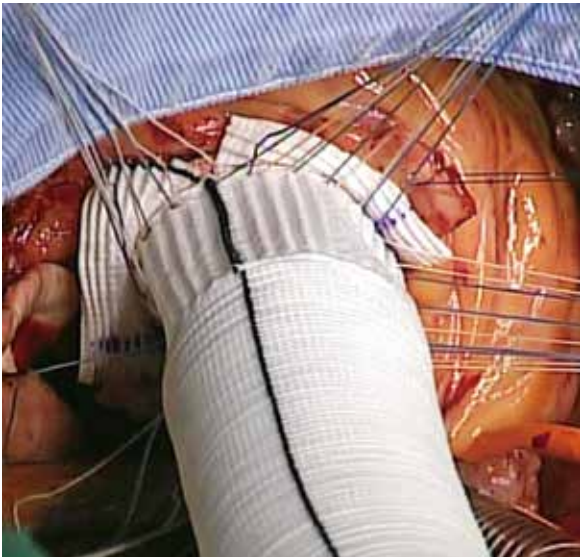
Department of Cardiac and Vascular Surgery,  
Dokkyo Medical University Heart Center 880  
Kitakobayashi, Mibu-machi, Shimotsuga-gun,  
Tochigi 321-0293, Japan



**Fig. 1** The “slit skirt”. The Valsalva graft collar is cut in three places.



**Fig. 3** A continuous 5-0 polypropylene suture is used to sew the residual aortic wall and the Valsalva graft collar to construct the proximal anastomosis line.



**Fig. 2** Pledgeted 2-0 polyester sutures are placed through the annulus from the aortic side to the ventricular side. The sutures are placed through the sewing cuff of the bioprosthetic valve and the upper edge of the Valsalva graft collar.

repeated every 20 min in the retrograde fashion. The aortic valve was resected, and coronary buttons were made in a regular fashion. The aortic wall was resected with a 7- to 10-mm remnant. After careful sizing of the aortic annulus, a valved conduit was constructed. We used a bioprosthetic valve and Gelweave Valsalva graft (Terumo CardioVascular Systems Corp, Ann Arbor, MI, USA) conduits that were 3 or 5 mm larger in size when compared with the valve. The collar was cut

in three places to avoid anastomosis complexity (Fig. 1). Everting pledgeted 2-0 polyester sutures were placed through the annulus from the aortic side to the ventricular side as tightly as possible. The sutures were placed through the sewing cuff of the bioprosthetic valve and the upper edge of the Valsalva graft collar (Fig. 2). The composite graft was placed at the intra-annular position, and sutures were tied down. Proximal hemostasis was achieved with a 5-0 polypropylene running suture line at the residual aortic wall and Valsalva graft collar (Fig. 3). The coronary buttons were re-implanted on the Valsalva sinus portion of the conduit with 5-0 polypropylene running sutures.

## PATIENTS

Informed consent was obtained from the patients. Between September 2008 and September 2014, 15 patients underwent a modified Bentall operation with the slit skirt technique at our institution. The clinical characteristics of the 15 patients are presented in Table 1. The median patient age was 68 years (range, 25 to 80 years) ; nine patients (60%) were male. Five patients (33%) had concomitant procedures (e.g., total arch replacement, hemi arch replacement, coronary artery bypass), and five patients (33%) had hypothermic circulatory arrest with antegrade cerebral perfusion. The median cardiopulmonary and aortic cross-clamp times were 242 and 192 minutes, respectively. No patients

**Table 1** Clinical characteristics of 15 cases

Case	Age	Gender	Disease	VG size (mm)	Valve size (mm)	Valve model	Concomitant procedures	OPE time (min)	CPB time (min)	XCL time (min)	Re-thoracotomy	Operative outcome (<30days)	Follow-up (months)	APA	Mid-term outcome	Cause of death
1	68	male	AAE	28	23	CEP	—	306	182	159	—	alive	76	—	alive	
2	65	female	AAE	26	21	CEP	CABG	310	167	137	—	alive	47	—	alive	
3	57	male	AAD	28	23	CEP	—	747	352	122	—	dead	0	—	—	CI
4	80	female	AAE	24	19	CEP	—	279	167	140	—	alive	39	—	alive	
5	73	male	AAE	26	21	CEP	—	308	203	180	—	alive	1	—	alive	
6	77	male	AAE	28	23	CEP	—	323	186	156	—	alive	4	—	dead	PVE, PGI
7	63	male	AAE	30	25	CEP	—	373	200	176	—	alive	29	—	alive	
8	74	female	AAD	24	21	ME	TAR, CABG	645	387	295	—	alive	24	—	alive	
9	68	male	AAE	28	25	ME	—	433	221	192	—	alive	23	—	alive	
10	80	female	CAD	24	19	ME	HAR	630	330	265	—	alive	21	—	alive	
11	25	female	AAE	26	23	ME	—	552	270	217	—	alive	21	—	alive	
12	58	male	AAE	30	25	CEP	—	641	319	212	—	alive	19	—	alive	
13	64	female	CAD	28	23	CEP	TAR, VSD	611	302	273	—	alive	12	—	dead	PGI
14	72	male	AAD	24	21	ME	—	569	262	201	—	alive	11	—	alive	
15	75	male	AAE	28	23	CEP	CABG	451	242	220	—	alive	3	—	alive	

AAE : annuloaortic ectasia, AAD : acute aortic dissection, CAD : chronic aortic dissection, VG : Vascutek® Gelweave Valsalva™ Grafts, CEP : CARPENTIER-EDWARDS PERIMOUNT Pericardial Aortic Bioprosthesis, ME : CARPENTIER-EDWARDS Magna Ease Pericardial Aortic Bioprosthesis, CABG : coronary artery bypass graft, TAR : total arch replacement, HAR : hemi-arch replacement, VSD : ventricular septal defect repair, OPE : operative, CPB : cardiopulmonary bypass, XCL : aortic cross-clamp, APA : anastmotic pseudoaneurysm, CI : cerebral infarction, PVE : prosthetic valve endocarditis, PGI : prosthetic graft infection.

had bleeding from the proximal anastomosis. No re-thoracotomy for bleeding was required. The hospital mortality was 7% (one death among 15 patients). The patient who died had type A dissection with preoperative massive cerebral infarction. During midterm follow-up (median period, 21 months), no patient had pseudoaneurysms at the proximal suture line.

## DISCUSSION

In 1968, Hugh Bentall and Antony De Bono first described the technique for replacement of the aortic root with a composite graft in patients with combined aortic valve and root diseases<sup>3)</sup>. The Bentall operation has become the gold standard with commercially available industry-made mechanical valved conduits in which lifetime anticoagulation is mandatory. Although the Japanese Circulation Society (JCS) guidelines still support the use of a mechanical valve prosthesis in patients of age 65 and younger, the actual practice pattern in Japan demonstrates a sharp decline in the use of mechanical aortic valve replacement implants<sup>4)</sup>. Possible explanations include the improved durability of

currently available bioprostheses, the morbidity associated with anticoagulation, and the possibility of transcatheter reintervention. Recently, many techniques that use the bioprosthetic valve conduit for the modified Bentall operation have been introduced for those patients<sup>5,6)</sup>.

The Valsalva graft has a unique design that closely matches the aortic root anatomy and that mimics the natural response of the sinuses of Valsalva. Because of this design, it has conceptual advantages for increased valve leaflet longevity by reducing the stress of leaflet closure. De Paulis et al. have shown that the potential benefit of the pseudo-sinuses of Valsalva can be exploited without the risk of affecting prosthetic valve performance<sup>7)</sup>. The combination of a bioprosthetic valve in a Valsalva graft may allow a maximal benefit of the pseudo-sinuses, promoting a less traumatic leaflet closure.

Bleeding from the proximal anastomosis of the composite graft is still one of the most notorious complications. Copeland et al. used the technique of a running suture between the cut edge of the supra-annular aor-

tic wall and the distal portion of the sewing ring to the aortic annulus<sup>1)</sup>. Michielon et al. described the “miniskirt” technique, wherein the proximal anastomosis is secured with a running suture, a buttressing aortic valve remnant, preserved native aortic valve leaflets, and the graft edge of the composite graft<sup>2)</sup>. Our technique was derived from these two techniques. Reinforcement suturing of the proximal anastomosis, as described in different techniques, is difficult and frustrating because of lack of space and poor visibility in that region. The modified composite graft presented in our technique was designed to avoid this complexity. The color eversion is facilitated by the three points cut (Fig. 2). In addition the three points cut matches the aortic valve commissures. Therefore anastomosis of residual aortic wall and Valsalva graft collar becomes easy. Bleeding from a proximal anastomosis with the Bentall operation occurs in the gap between the composite graft and the aortic annulus. Therefore, covering the Valsalva graft collar is a reasonable method to prevent bleeding. Further follow-up is needed to evaluate the long-term risk and benefit of this strategy.

In conclusion, the slit skirt technique could be useful to prevent bleeding from the proximal anastomosis after the Bentall operation.

**Disclosure Statement :**

There are no conflicts of interest.

**REFERENCES**

- 1) Copeland 3rd JG, Rosada LJ, Snyder SL : New technique for improving hemostasis in aortic root replacement with composite graft. *Ann Thorac Surg* **55** : 1027-1029, 1993.
- 2) Michielon G, Salvador L, Da Col U, et al : Modified button-Bentall operation for aortic root replacement : the miniskirt technique. *Ann Thorac Surg* **72** : 1059-1064, 2001.
- 3) Bentall H, De Bono A : A technique for complete replacement of the ascending aorta. *Thorax* **23** : 338-339, 1968.
- 4) Masuda M, Kuwano H, Okumura M, et al : Thoracic and cardiovascular surgery in Japan during 2012 : Annual report by The Japanese Association for Thoracic Surgery. *Gen Thorac Cardiovasc Surg* **62** : 734-764, 2014.
- 5) Tabata M, Takayama H, Bowdish ME, et al : Modified Bentall operation with bioprosthetic valved conduit : Columbia University experience. *Ann Thorac Surg* **87** : 1969-1970, 2009.
- 6) Albertini A, Dell'Amore A, Zussa C, et al : Modified Bentall operation : the double sewing ring technique. *Eur J Cardiothorac Surg* **32** : 804-806, 2007
- 7) De Paulis R, Schmitz C, Scaffa R, et al : In vitro evaluation of aortic valve prosthesis in a novel valved conduit with pseudosinuses of Valsalva. *J Thorac Cardiovasc Surg* **130** : 1016-1021, 2005.