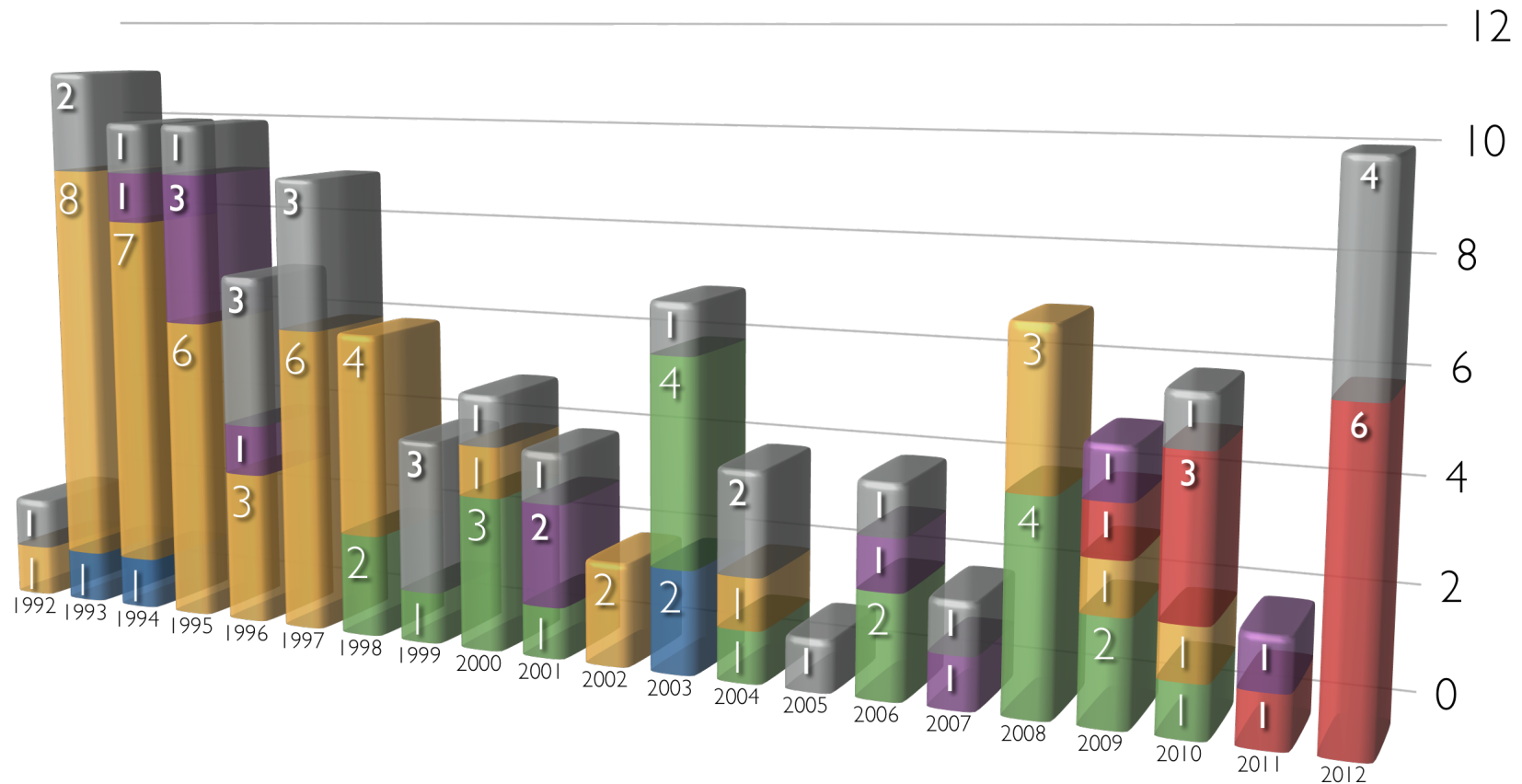


Approach to the Frontozygomatic Suture for ZMC fractures

■ lateral brow:	4	■ lateral upper blepharoplasty:	21
■ lateral canthotomy:	44	■ extended transconjunctival:	11
■ coronal:	11	■ laceration:	27



118 frontozygomatic suture fixation in 150 acute ZMC fractures
1992 - 2012