

Original

# Matrix Metalloproteinase-8-positive Neutrophils in Nasal Polyps Are Involved in the Disease Progression of Eosinophilic Chronic Rhinosinusitis : a Clinico-pathological Study

Makoto Akutsu\*, Hiroaki Kanaya, Takashi Kashiwagi,  
Yasuhiro Tsunemi and Shin-ichi Haruna

*Department of Otorhinolaryngology-Head and Neck Surgery, Dokkyo Medical University*

## SUMMARY

**Background** : Eosinophilic chronic rhinosinusitis (ECRS) is an intractable subtype of chronic rhinosinusitis (CRS), which is characterized by marked polyp formation. This study is intended to understand the involvement of matrix metalloproteinase-8-positive (MMP-8+) neutrophils in the disease progression of ECRS by comparing it to that of non-ECRS.

**Methods** : Nasal polyps (NPs) in patients with ECRS and non-ECRS were investigated using immunofluorescence staining, and the ratios of MMP-8+ neutrophils in NPs were evaluated in combination with histological and clinical parameters.

**Results** : MMP-8+ neutrophils in NP were clearly identified in immunofluorescence staining. The percentage of MMP-8+ neutrophils in NPs was significantly increased in the ECRS group compared to that in the non-ECRS group. The ECRS group presented higher tissue remodeling scores than the non-ECRS group ; however, the percentage of MMP-8+ neutrophils was not correlated with the severity of tissue remodeling. Furthermore, the percentage of MMP-8+ neutrophils was mildly inverse correlated with the remodeling scores in ECRS patients. Although the ECRS group presented higher values than the non-ECRS group with respect to computed tomography scores, endoscopic polyp scores, olfaction recognition thresholds, and the percentage of MMP-8+ neutrophils showed a statistically significant correlation only among the subgroups defined by computed tomography scores in the ECRS group.

**Conclusions** : This study suggests that MMP-8+ neutrophils may participate in the progression of ECRS, particularly by initiating NP formation in the paranasal sinus mucosa at the early stages of ECRS. MMP-8+ neutrophils might become a candidate of nasal therapeutic target for patients with ECRS.

**Key Words** : Tissue remodeling, Histopathology, Computed tomography score, Polyp score, Olfaction recognition threshold

---

Received September 24, 2020 ; accepted October 5, 2020

Reprint requests to : Makoto Akutsu

Department of Otorhinolaryngology-Head and Neck Surgery, Dokkyo Medical University, 880 Kitakobayashi, Mibu, Tochigi 321-0293, Japan

## INTRODUCTION

Chronic rhinosinusitis (CRS) is a common upper airway disease worldwide and can lead to nasal polyps (NPs) due to inflammatory processes in the paranasal sinus mucosa. Especially eosinophilic chronic rhinosinusitis (E CRS)<sup>1)</sup>, an intractable subtype of CRS, which is characterized by prominent polyp formation with severe eosinophilic infiltration and clinically manifests as progressive olfactory dysfunction, nasal obstruction, and mucinous discharge. In Japan, the diagnostic criteria of E CRS became widely known due to the JESREC study<sup>2,3)</sup>. The pathogenesis of E CRS remains uncertain. However, it is expected that various enterotoxins produced by *Staphylococcus* species stimulate Th2 immunocompetent cells and cause marked inflammatory infiltrates consisting mainly of eosinophils<sup>1-4)</sup> in paranasal sinus tissues via diverse immunological pathways. Besides, a similarity between CRS and bronchial asthma (BA) has been suggested because CRS and BA occur in many patients concomitantly and exacerbate simultaneously<sup>5)</sup>. Both diseases have similar histopathological features, namely, an intense eosinophilic infiltration<sup>5-7)</sup> that has been recognized as an eosinophil-associated allergic disorder.

The NPs occur as the result of tissue remodeling and reflect pathological tissue reconstruction processes characterized by epithelial damage, metaplasia, basement membrane (BM) thickening, gland hyperplasia, and stromal fibrosis due to abnormal accumulation of extracellular matrix (ECM)<sup>8,9)</sup>. Degradation of ECM and BM components in local paranasal sinus tissue is tightly regulated by proteolytic activities of matrix metalloproteinases (MMPs), and altered MMP expression can eventually induce remodeling as an abnormal tissue reconstruction process<sup>10-13)</sup>. Especially MMP-8, which is primarily produced by activated neutrophils and degrades mainly the BM<sup>14,15)</sup>. Previous reports describe similar histopathological features of tissue remodeling in CRS and BA<sup>7)</sup>, and high numbers of neutrophils are present in the lower airway of patients with chronic severe BA<sup>16,17)</sup>.

Based on previous histopathological observations, we developed a considerable interest in neutrophil infiltration in NPs of E CRS patients. Although several studies focused on the role of eosinophils in patients

with NPs<sup>3,5,18,19)</sup>, no study has investigated yet how neutrophils are involved in the pathophysiology of E CRS. We hypothesized that tissue-infiltrating neutrophils participate in E CRS progression, and specifically MMP-8-positive (MMP-8+) neutrophils may be an exacerbating factor. Using various histological and clinical approaches, we assessed in the current study the percentages of MMP-8+ neutrophils in NPs of E CRS patients and evaluated the relationship of these neutrophils to E CRS progression. According to our data, we observed a relationship between MMP-8+ neutrophils and computed tomography (CT) scores in E CRS patients. This indicated that MMP-8+ neutrophils could be involved in NP formation of the local paranasal sinus mucosa at the early stages of E CRS.

## METHODS

### *Study population and sample collection*

This study enrolled in-patients who underwent endoscopic sinus surgery at the Department of Otorhinolaryngology, Head and Neck Surgery of the Dokkyo Medical University Hospital between April 2017 and December 2019. All patients with NP were diagnosed according to the algorithm of the JESREC score<sup>2)</sup> based on nasal endoscopy examination, CT scan, and eosinophil count in the NP tissue. Accordingly, the study population was divided into two groups of 50 E CRS patients (38 males, 12 females, aged 23-77 years) and 32 non-E CRS patients (22 males, 10 females, aged 11-74 years ; Table 1).

Their NP tissue samples obtained during the endoscopic sinus surgery were divided into two sections for further investigations : one was processed for histopathological evaluations and immunofluorescent studies, whereas the other was cryopreserved for protein extraction. The uncinate process mucosa was collected from patients without an inflammatory disease in the ethmoid sinuses and used for control measurements of the active form of MMP-8 protein using enzyme-linked immunosorbent assay (ELISA). This research was approved by the Ethics Committee of Dokkyo Medical University Hospital, and informed consent was obtained from every participant.

### *Detection of MMP-8+ neutrophils in NP tissue*

Because neutrophils are often difficult to identify by

**Table 1** Clinical characteristics of the study groups

	n	Age (years)		Sex	Endoscopic	Lund-Mackay	T&T
		median	range	Male : Female	polyp score	CT score	olfactometry
ECRS group	50	52	23-77	38 : 12	6.01 ± 0.92	16.56 ± 4.40	4.95 ± 1.48
non-ECRS group	32	50	11-74	22 : 10	4.75 ± 1.44	12.75 ± 5.65	3.44 ± 2.10

\* :  $p < 0.05$ , \*\* :  $p < 0.001$ 

standard hematoxylin and eosin (HE) staining due to their cytomorphologic diversity, we targeted the neutrophil elastase<sup>20)</sup> as a specific marker to detect tissue-infiltrating neutrophils. We prepared a monoclonal anti-human neutrophil elastase antibody (Dako Agilent, Santa Clara, CA, USA) labeled with Alexa Fluor 488<sup>®</sup> (Thermo Fisher, Waltham, MA, USA) for immunofluorescence staining. Furthermore, an anti-human MMP-8 antibody (Kyowa Pharma Chemical, Toyama, Japan) labeled with Alexa Fluor 555<sup>®</sup> (Thermo Fisher) was used to detect MMP-8+ neutrophils. 4- $\mu$ m thick Frozen sections from freshly obtained NP tissues were mounted on poly-L-lysine-coated slides. After fixation with acetone at  $-20^{\circ}\text{C}$ , each section was incubated with the described antibodies diluted 1 : 100 respectively at  $4^{\circ}\text{C}$  overnight. After the incubation, sections were gently washed and mounted with DAPI Fluoromount-G<sup>®</sup> (Southern Biotech, Birmingham, AL, USA) for nuclear stain, and fluorescent images were acquired subsequently using a BX53 microscope and a DP80 digital camera with cellSense<sup>®</sup> software (Olympus, Tokyo, Japan). Five fields of epithelial and subepithelial areas per section were randomly selected at  $200\times$  magnification, and the percentage of MMP-8+ neutrophils, i.e., the cells double-positive for neutrophil elastase and MMP-8, was determined by three independent observers.

#### ELISA for MMP-8 detection

Cryopreserved NPs from the ECRS (n=10) and non-ECRS (n=10) groups were minced, and the total protein was extracted using a cell lysis buffer (Cell Signaling Technology, Danvers, MA, USA) admixed with proteinase inhibitor cocktail (Sigma-Aldrich, St. Louis, MO, USA). The total protein in the tissue lysate was adjusted to a concentration of 2 mg/ml. As the control, tissue samples of the uncinata process mucosa (n=10) were prepared using the same proce-

dures. To quantify the tissue concentrations of activated MMP-8 protein with an ELISA, the human MMP-8 activity assay kit (QuickZyme Biosciences, Leiden, The Netherlands) was used according to the manufacturer's instructions. The prepared samples were transferred into the 96-well plates provided by the manufacturer and incubated for 24 h at  $37^{\circ}\text{C}$  with the standard chemicals of the kit. The optical density values at 405 nm were measured using the VERSAmax<sup>®</sup> microplate reader (Molecular Devices, San Jose, CA, USA), and the concentrations of the active form of MMP-8 proteins were calculated based on the standard curve.

#### Evaluation of tissue remodeling in the NP

4- $\mu$ m thick Frozen sections were cut from freshly obtained NP tissue samples, and each section was stained with HE to observe the histological manifestations of the disease. In parallel, Alcian blue and periodic acid Schiff reaction (Al-PAS) to evaluate goblet cell metaplasia and thickening of the BM, as well as Elastica-Goldner (EG) staining to measure the degree of stromal fibrosis, were employed. Manifestations of tissue remodeling included epithelial damage, BM thickening, glandular hyperplasia, goblet cell metaplasia, reserve cell hyperplasia, and squamous metaplasia were noted. Each manifestation was scored according to the method of Wang et al.<sup>9)</sup> and Ponikau et al.<sup>5)</sup> described in Table 2.

The histological severity was assessed by aggregated scores and classified into three subgroups : mild (0-3), moderate (4-6), and severe (7-10). Tissue sections were examined by three independent observers blinded from clinical and other patient data. To evaluate the stromal fibrosis of an NP, EG staining images were acquired, and the percentage of the fibrotic area was calculated in 10 fields at  $200\times$  magnification using the WinROOF<sup>®</sup> image processing soft-

**Table 2** Description of the tissue remodeling scores

Remodeling features	Histological changes ( <b>score</b> )
Epithelial damage	Epithelium intact ( <b>0</b> )
	Cilia absent ( <b>1</b> )
	Upper cell layer eroded and basal cell layer intact ( <b>2</b> )
	Epithelium eroded ( <b>3</b> )
Basement membrane (BM) thickening	No BM visible ( <b>0</b> )
	Mild BM thickening (<10 $\mu\text{m}$ ) ( <b>1</b> )
	Moderate BM thickening (10-20 $\mu\text{m}$ ) ( <b>2</b> )
	Severe BM thickening (>20 $\mu\text{m}$ ) ( <b>3</b> )
Gland hyperplasia	Less than 3 glands per 200 $\times$ viewing field ( <b>0</b> )
	More than 4 glands per 200 $\times$ viewing field ( <b>1</b> )
Squamous cell metaplasia	Negative ( <b>0</b> )    Positive ( <b>1</b> )
Reserve cell hyperplasia	Negative ( <b>0</b> )    Positive ( <b>1</b> )
Goblet cell metaplasia	Negative ( <b>0</b> )    Positive ( <b>1</b> )

Histological severity was classified based on the total scores into three subgroups : mild (**0-3**), moderate (**4-6**), and severe (**7-10**).

ware (Mitani Visual System, Tokyo, Japan). The degree of stromal fibrosis was compared among three subgroups with arbitrarily chosen thresholds : mild (<20%), moderate (20-40%), and severe (>40%).

#### *Evaluation of the clinical CRS manifestations*

Peripheral blood samples were collected from all patients to examine the leukocytes and determine the fractions of neutrophils and eosinophils. Each patient underwent preoperatively a nasal endoscopy to determine the endoscopic polyp score<sup>21</sup>. This score is based on the polyp sizes in the right and left nasal cavities resulting in two scores between 0 and 4 each, with a higher score indicating a worse status. The final endoscopic polyp score was defined as the sum of the right and left scores and divided into three subgroups : mild (0-2), moderate (3-5), and severe (6-8). Based on the Lund-Mackay CT scoring system<sup>22</sup>, CT scan findings were assessed with scores between 0 and 24, and a higher score demonstrated a more severe inflammatory condition. These CT scores were also subgrouped into three classes : mild (0-8), moderate (9-16), and severe (17-24). To evaluate a patient's olfactory performance, the T&T olfactometer (Daiichi Yakuhin Sangyo, Tokyo, Japan) was employed with the following five odorous substances :  $\beta$ -phenyl ethyl alcohol, methyl cyclopentenolone,

isovaleric acid,  $\gamma$ -undecalactone, and skatole. The recognition thresholds for each odorant were obtained and averaged according to the procedure described in Kashiwagi et al.<sup>23</sup>. According to the T&T recognition threshold, olfactory dysfunction was categorized into five classes as normosmia, mild hyposmia, moderate hyposmia, severe hyposmia, and anosmia when the mean recognition threshold was 1.1 or less, 1.1 to 2.5, 2.6 to 4.0, 4.1 to 5.5, and 5.6 or higher, respectively. Table 1 summarizes the clinical characteristics of both patient groups enrolled in this study.

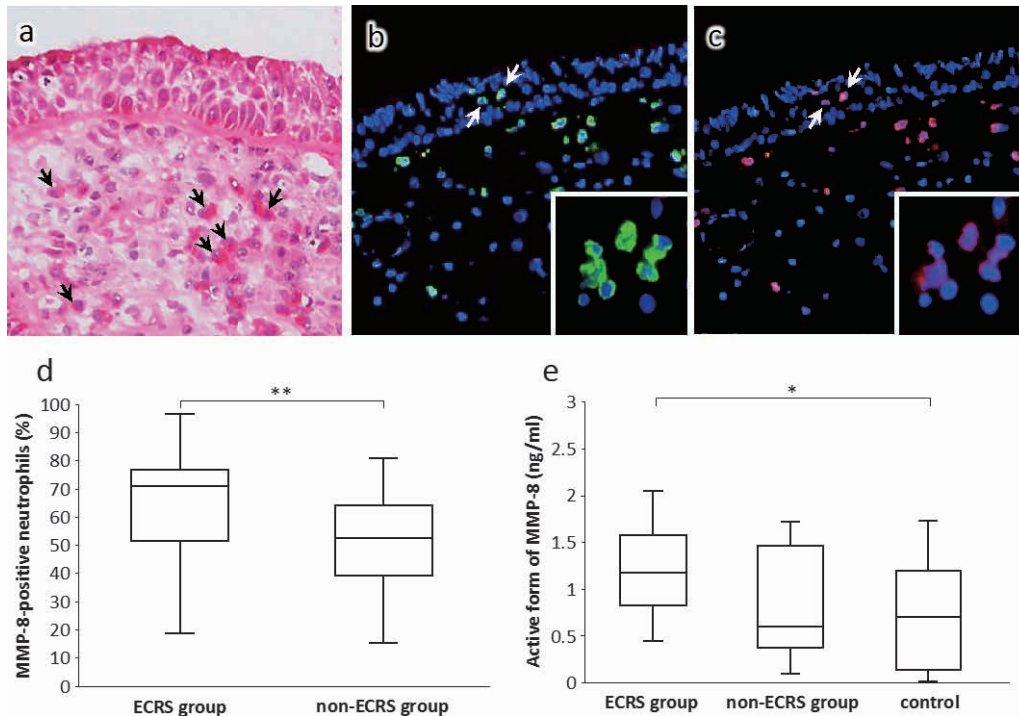
#### *Statistical methods*

Data are expressed as the median and interquartile range (IQR). The Kruskal-Wallis test with Bonferroni correction was used to analyze differences between various groups, and significance was accepted for  $p < 0.05$ . Statistical analyses were performed with IBM SPSS<sup>®</sup> statistics software version 26 (IBM, New York, NY, USA), and data are presented as box-and-whisker graphs.

## RESULTS

#### *Localization and percentages of MMP-8+ neutrophils in NPs*

Although various degrees of eosinophilic infiltration were clearly observed in NPs obtained from ECRS



**Fig. 1** Histopathology and percentage of MMP-8+ neutrophils in ECRS

Representative histological picture of an NP from an ECRS patient (HE, 200 $\times$ ) (a). Eosinophils are well demarcated (arrows), whereas neutrophils are difficult to identify. Immunofluorescence staining for elastase (green) (b) and MMP-8 (red) (c) with nuclear staining (blue) (200 $\times$ ; inserts: higher magnification). Neutrophils infiltrate the intraepithelial region (arrows). The percentages of MMP-8+ neutrophils in NPs are significantly higher in the ECRS group than in the non-ECRS group (d). The concentration of the active form of MMP-8 protein is significantly higher in NP tissue samples of the ECRS group than in samples of the control group, but there is no statistically significant difference between the ECRS and non-ECRS groups (e). \*  $p < 0.05$ , \*\*  $p < 0.001$ . MMP-8: metalloproteinase-8; MMP-8+: metalloproteinase-8-positive; NP: nasal polyp; ECRS: eosinophilic chronic rhinosinusitis; HE: hematoxylin and eosin

patients (Fig. 1a), neutrophils were difficult to identify in HE staining. By contrast, immunofluorescence staining for neutrophil elastase demonstrated the presence of neutrophils in intraepithelial regions and the stroma of NPs (Fig. 1b). MMP-8+ cells were also evident (Fig. 1c), and cells double-positive for both targets were counted as MMP-8+ neutrophils. The percentage of MMP-8+ neutrophils in the NP was significantly higher in the ECRS group (median 70.9%, IQR 51.5–76.9%) than in the non-ECRS group (median 52.5%, IQR 39.3–64.8%; Fig. 1d).

#### *Concentration of the active form of MMP-8 protein in NP tissue*

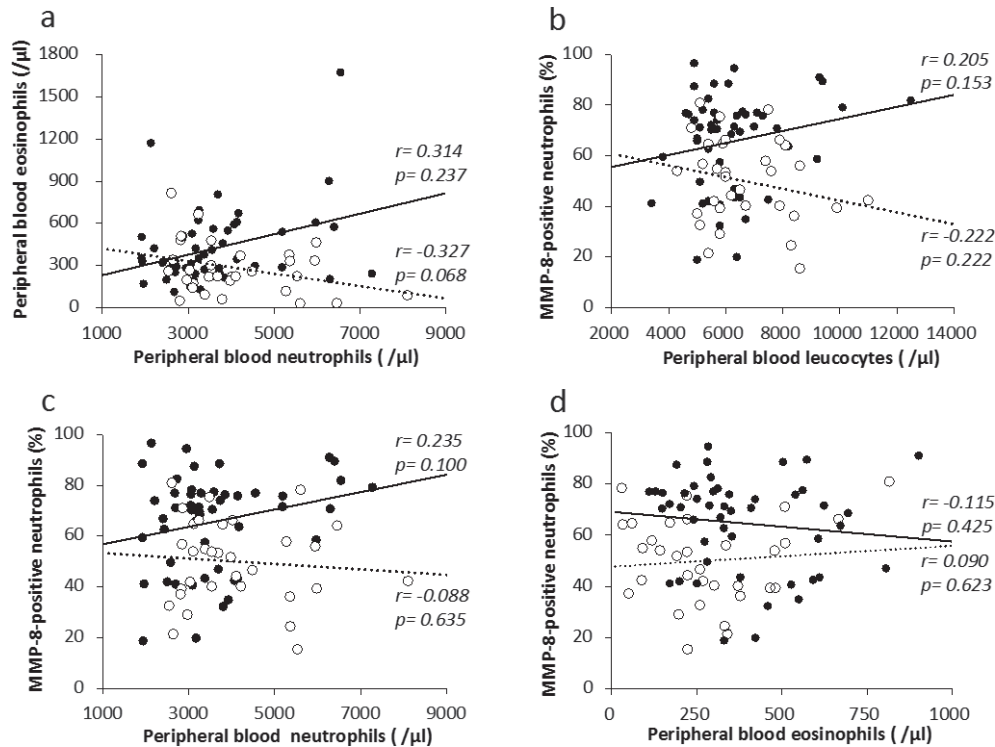
The concentration of the active form of MMP-8 protein was significantly higher in NP tissue samples of the ECRS group (median 1.18 ng/ml, IQR 0.83–

1.58 ng/ml) than in samples of the control group (median 0.70 ng/ml, IQR 0.14–1.20 ng/ml; Fig. 1e). There was no statistically significant difference between the ECRS and non-ECRS groups (median 0.61 ng/ml, IQR 0.37–1.47 ng/ml).

#### *MMP-8+ neutrophils and peripheral blood leucocytes*

As shown in Fig. 2a, the number of peripheral blood neutrophils showed a mild positive correlation with eosinophils in the ECRS group ( $r = 0.314$ ,  $p = 0.237$ ), but a negative correlation in the non-ECRS group ( $r = -0.327$ ,  $p = 0.068$ ). There were no additional significant associations between the percentages of MMP-8+ neutrophils in NPs and the numbers of peripheral blood leukocytes or their fractions in either group (Fig. 2b–d).





**Fig. 2** Numbers of peripheral neutrophils and eosinophils in the ECRS and non-ECRS groups. In the ECRS group, there is a mildly positive correlation between the numbers of peripheral neutrophils and eosinophils ( $r=0.314$ ). By contrast, an inverse correlation can be observed in the non-ECRS group ( $r=-0.327$ ) (a). The percentages of MMP-8+ neutrophils in NPs are not significantly correlated to the numbers of peripheral leucocytes (b), neutrophils (c), and eosinophils (d). “●” and solid lines, ECRS group; “○” and dotted lines, non-ECRS group. MMP-8+ : metalloproteinase-8-positive; NPs : nasal polyps; ECRS : eosinophilic chronic rhinosinusitis

#### MMP-8+ neutrophils and tissue remodeling features

Tissue remodeling scores of NPs in the ECRS group (median 7, IQR 5–8) indicated a significantly increased severity compared to those in the non-ECRS group (median 3, IQR 1–3;  $**p<0.001$ ; Fig. 3a). A mildly inverse correlation was observed between the percentage of MMP-8+ neutrophils and the severity of tissue remodeling in the ECRS group ( $r=-0.425$ ,  $p<0.05$ ; Fig. 3b). By contrast, no specific correlation was detected in the non-ECRS group. In the ECRS group, the percentages of MMP-8+ neutrophils tended to decrease with increasing tissue remodeling scores, although there were no statistically significant differences (Fig. 3c). The non-ECRS group did not present any specific trends regarding these parameters (Fig. 3d).

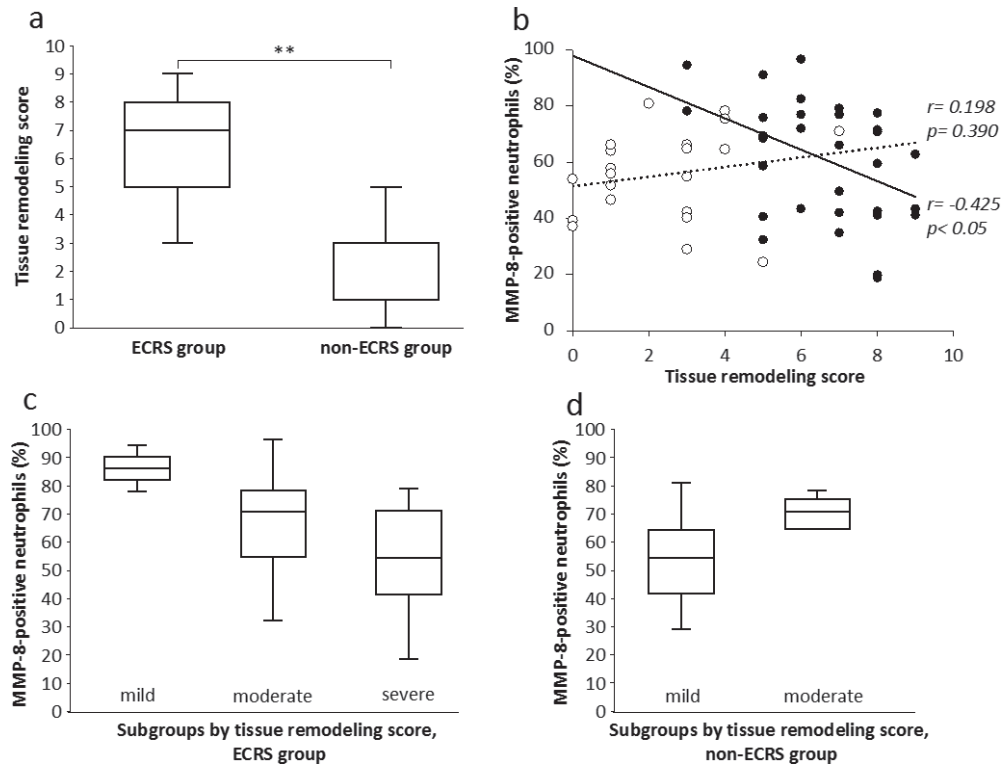
Stromal fibrosis in the NPs of the ECRS group was

more severe (median 35.0%, IQR 27.0–45.0%) than in those of the non-ECRS group (median 22.8%, IQR 15.0–33.2%;  $*p<0.05$ ; Fig. 4a). However, fibrosis was not correlated to the percentage of MMP-8+ neutrophils in the NP (Fig. 4b). The fibrosis subgroups in both ECRS and non-ECRS groups did not present statistically significant differences (Fig. 4c, d).

#### MMP-8+ neutrophils and clinical CRS manifestations

Regarding clinical parameters, the endoscopic polyp scores, the Lund-Mackay CT scores, and the results of the T&T olfactometry presented significant differences between the ECRS and non-ECRS groups (Table 1).

The ECRS group had significantly higher Lund-Mackay CT scores (median 16.5, IQR 14.0–20.0) than the non-ECRS group (median 11.0, IQR 9.0–17.3;  $*p$



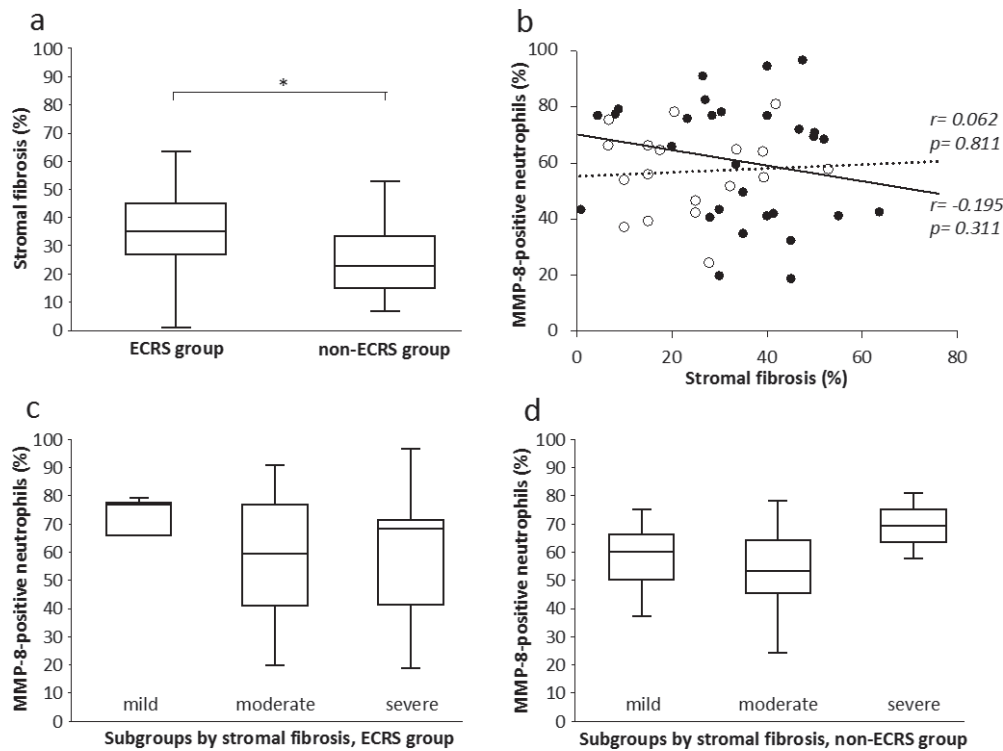
**Fig. 3** Tissue remodeling scores in the ECRS and non-ECRS groups and subgroups. Tissue remodeling scores of NPs indicate a significantly increased disease severity in the ECRS group compared to that in the non-ECRS group (\*\* $p < 0.001$ ) (a). A mildly negative correlation is shown between the percentages of MMP-8+ neutrophils and the tissue remodeling scores in the ECRS group ( $r = -0.425$ ) (b). “●” and solid lines, ECRS group; “○” and dotted lines, non-ECRS group. In ECRS subgroups, the percentages of MMP-8+ neutrophils tend to decrease with increasing tissue remodeling scores (c) whereas the non-ECRS subgroups do not show a distinct trend (d). MMP-8+ : metalloproteinase-8-positive ; NPs : nasal polyps ; ECRS : eosinophilic chronic rhinosinusitis

$< 0.05$  ; Fig. 5a). In the ECRS group, the CT scores had a mildly positive correlation with the percentages of MMP-8+ neutrophils in NPs ( $r = 0.369$ ,  $p < 0.05$  ; Fig. 5b). Moreover, the percentages of MMP-8+ neutrophils in NPs of the ECRS group were significantly different for the mild (median 41.8%, IQR 41.4–42.2%), moderate (median 68.5%, IQR 46.5–73.0%), and severe (median 75.8%, IQR 66.9–82.0% ;  $*p < 0.05$  ; Fig. 5c) subgroups according to the CT score. These subgroups showed no differences in the non-ECRS group (Fig. 5d).

The endoscopic polyp score was significantly higher in the ECRS group (median 6, IQR 6–7) than in the non-ECRS group (median 5, IQR 4–6 ; \*\* $p < 0.001$  ; Fig. 6a) but no relationship was identified to the percentage of MMP-8+ neutrophils in the NPs of either

group (Fig. 6b). Similarly, in both groups there were no differences between subgroups by polyp score (Fig. 6c, d).

The olfaction recognition threshold was significantly worse in the ECRS group (median 5.8, IQR 4.1–5.8) than in the non-ECRS group (median 3.3, IQR 1.4–5.8 ; \*\* $p < 0.001$  ; Fig. 7a). This parameter had a mildly positive correlation to the percentage of MMP-8+ neutrophils in NPs of the ECRS group ( $r = 0.321$ ,  $p < 0.05$  ; Fig. 7b). The percentages of MMP-8+ neutrophils in the NP tended to increase with progressing olfactory dysfunction in the ECRS group without reaching statistical significance (Fig. 7c). By contrast, there was no identifiable tendency in the non-ECRS group (Fig. 7d).



**Fig. 4** Stromal fibrosis in the ECRS and non-ECRS groups and subgroups  
Stromal fibrosis in NPs is significantly increased in the ECRS group compared to that in the non-ECRS group (\* $p < 0.05$ ) (a) but there is no relationship to MMP-8+ neutrophils (b). "●" and solid lines, ECRS group ; "○" and dotted lines, non-ECRS group. Both groups do not have significant differences among their subgroups (c, d). MMP-8+ : metalloproteinase-8-positive ; NPs : nasal polyps ; ECRS : eosinophilic chronic rhinosinusitis

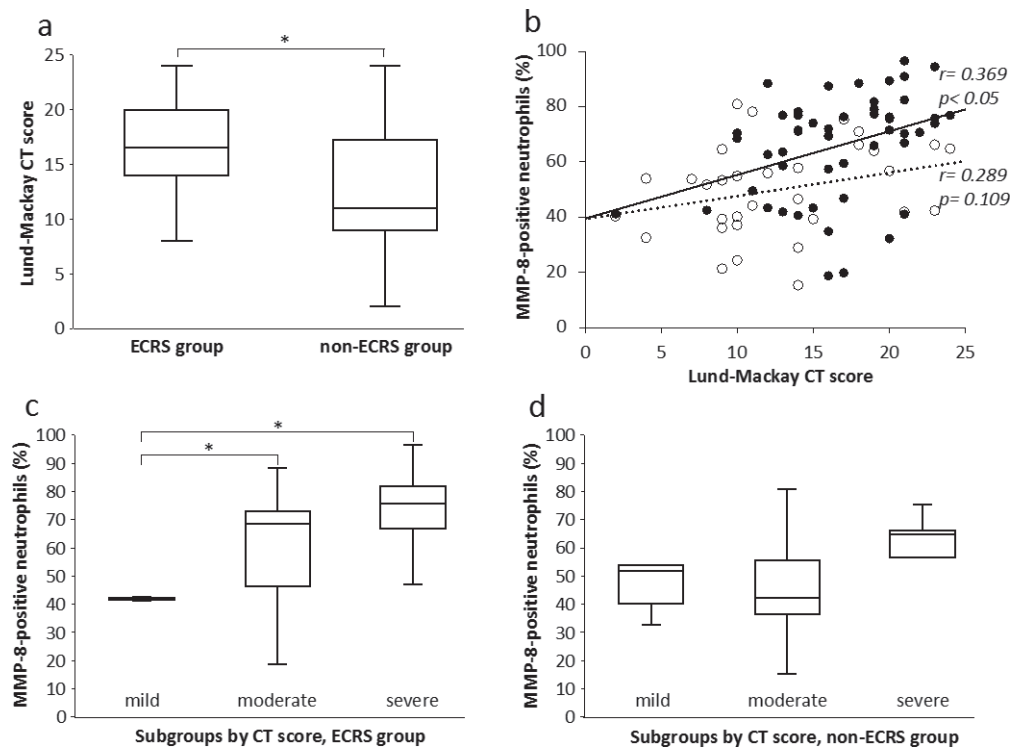
## DISCUSSION

In this study, we successfully visualized infiltrating neutrophils in NP tissues using immunofluorescence staining. The percentage of MMP-8+ neutrophils was significantly higher in the ECRS group than in the non-ECRS group. These MMP-8+ neutrophils were observed not only in the stroma but also in the intraepithelial regions. This finding suggested that activated neutrophils located in the stroma could infiltrate these intraepithelial regions through the BM while secreting MMP-8 and degrading ECM components of the BM. Moreover, the concentration of the active form of MMP-8 protein was evidently elevated in NP tissue samples. To our knowledge, this is the first report to demonstrate the high expression of MMP-8 and its activation in neutrophils of patients with ECRS. This is supported by the study by Prikk et al.<sup>24</sup> demonstrating that the active form of MMP-8 plays an important role in the airway destruction and

tissue remodeling in BA patients because MMP-8 most efficiently catalyzes the degradation of type I collagen, which is the major constituent of the BM. Similarly, Kikuchi et al.<sup>25</sup> showed that neutrophils activated by interleukin (IL)-8 may influence trans-BM migration of eosinophils *in vitro*. Kostamo et al.<sup>26</sup> described an elevated concentration of activated MMP-8 and IL-8 in the nasal lavage of CRS patients and suggest the possibility of tissue remodeling caused by MMP-8 in these patients.

The percentages of MMP-8+ neutrophils in NP tissues did not have a statistical correlation with the numbers of peripheral neutrophils or eosinophils in all patients. However, ECRS patients showed a mild positive correlation between the numbers of peripheral neutrophils and eosinophils. A recent study in adult BA patients demonstrates that blood neutrophilia and eosinophilia are associated with asthma exacerbation and bronchial hypersensitivity, respectively<sup>27</sup>. We speculate that the role of MMP-8+ neutrophils could





**Fig. 5** Lund-Mackay CT scores in the ECRS and non-ECRS groups and subgroups

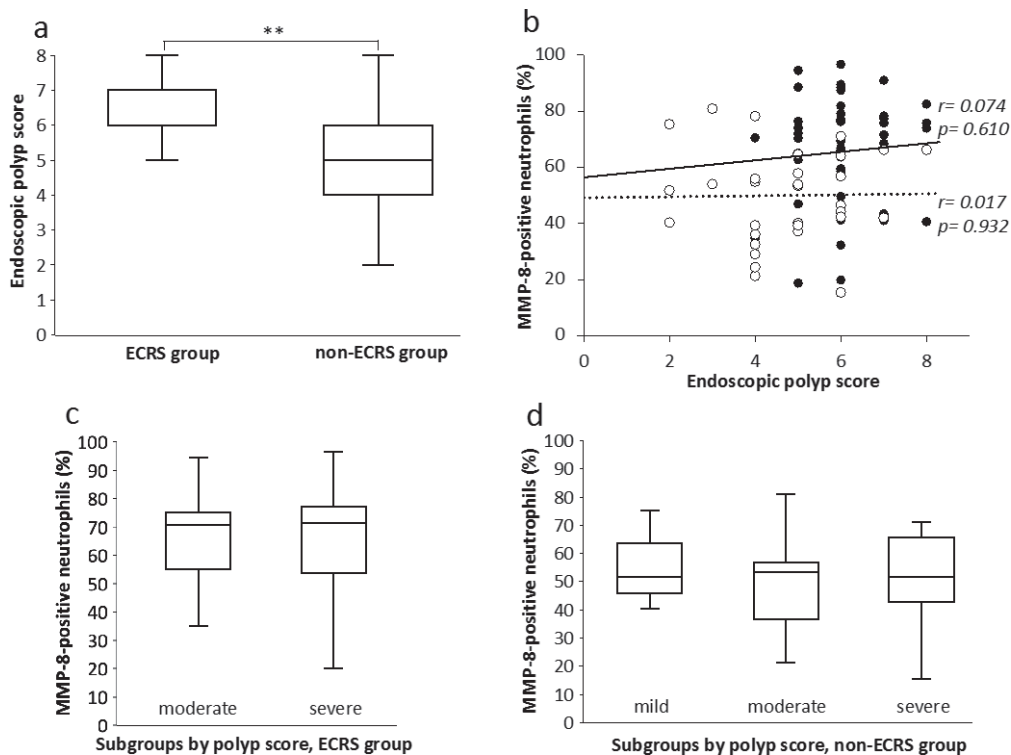
In the Lund-Mackay CT scores, the ECRS group has significantly higher scores than the non-ECRS group (a) and a mildly positive correlation to MMP-8+ neutrophils in NPs ( $r=0.369$ ) (b). “●” and solid lines, ECRS group; “○” and dotted lines, non-ECRS group. In the ECRS group, the percentages of MMP-8+ neutrophils in NPs are significantly different between subgroups defined by the CT score ( $*p<0.05$ ) (c). The non-ECRS group shows no subgroup differences (d). CT: computed tomography; MMP-8+: metalloproteinase-8-positive; NP: nasal polyp; ECRS: eosinophilic chronic rhinosinusitis

be limited to local NP tissue because the percentages of MMP-8+ neutrophils in NPs did not reflect the indices of systemic inflammation such as eosinophil counts in peripheral blood.

Regarding tissue remodeling and stromal fibrosis, the ECRS group presented evidently higher scores than the non-ECRS group. Since NP is thought to be the final product of pathological remodeling processes including collagen deposition, this result may accurately reflect the disease severity and intractability of ECRS<sup>1,2</sup>). Contrary to our expectations, the percentages of MMP-8+ neutrophils in NP showed a mild inverse correlation with the remodeling scores in ECRS patients, although the degree of stromal fibrosis was not correlated with it. Nakayama et al.<sup>3</sup>) analyzed inflammatory mediators in NPs of patients with ECRS, and they mentioned that the mildly affected subgroup expressed higher IL-8 mRNA expression levels than

the more severely affected groups. In our data, stromal fibrosis was also clearly more severe in the ECRS group than in the non-ECRS group, but we observed no subgroup differences. According to Van Bruaene et al.<sup>8</sup>), stromal fibrosis caused by collagen deposition is initiated by TGF- $\beta$  at early CRS stages. They suggest that TGF- $\beta$  plays a central role in the initiation of NPs. Thus, we presume that MMP-8+ neutrophils could be involved in the incipient tissue remodeling at the early stages and/or in mildly affected cases of ECRS. However, MMP-8+ neutrophils may not reflect stromal fibrosis in ECRS because fibrosis is the result of prolonged local inflammation.

The ECRS group presented higher scores for the examined clinical parameters than the non-ECRS group. Although the percentages of MMP-8+ neutrophils in NPs of the ECRS group were mildly correlated with the CT score and olfactory dysfunction, we



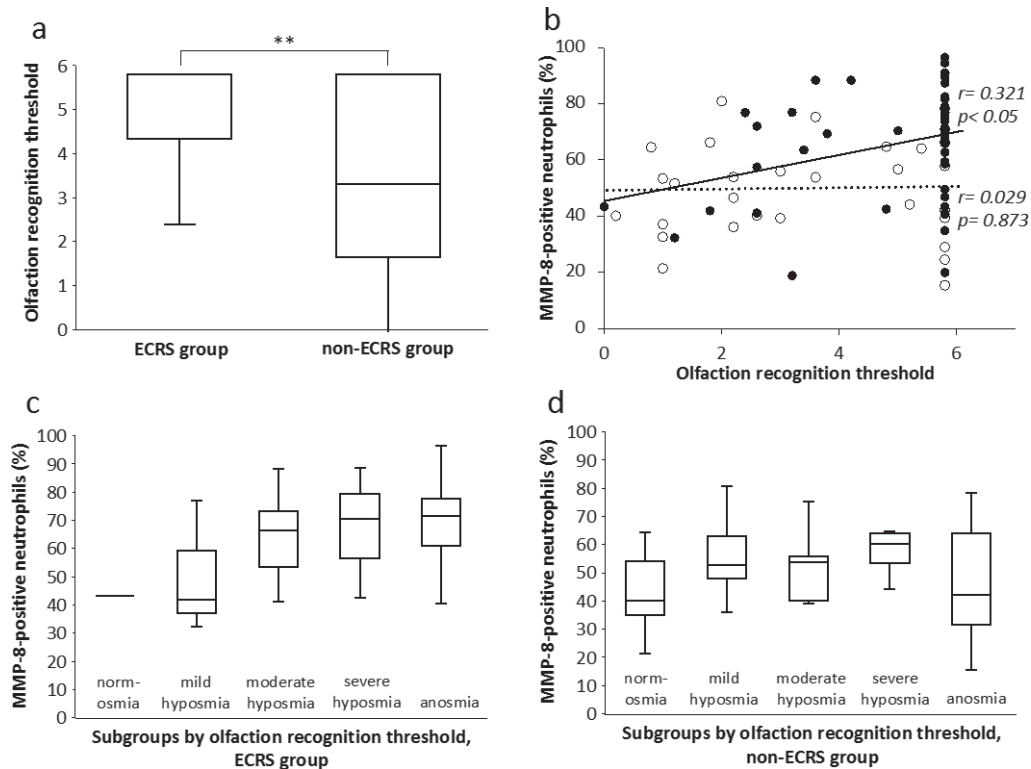
**Fig. 6** Endoscopic polyp scores in the ECRS and non-ECRS groups and subgroups  
 The endoscopic polyp scores are significantly higher in the ECRS group than in the non-ECRS group (\*\*  $p < 0.001$ ) (a) but are not correlated to the percentages of MMP-8+ neutrophils in NPs of both groups (b). “●” and solid lines, ECRS group; “○” and dotted lines, non-ECRS group. There are no subgroup differences in both groups (c, d). MMP-8+ : metalloproteinase-8-positive; NPs : nasal polyps; ECRS : eosinophilic chronic rhinosinusitis

particularly wanted to focus on the statistical differences in CT scores among the ECRS subgroups. Malinsky et al.<sup>28)</sup> examined the role of MMP-1, MMP-2, and MMP-9 in CRS patients with NP and observed no correlation between the gene expression of MMPs and CT scan findings. They concluded that MMP-dependent tissue remodeling in NP cannot be evaluated by gross CT scans because the Lund-Mackay CT score classifies only the mucosal thickening of the paranasal sinus. In the present study, the percentages of MMP-8+ neutrophils in NPs of ECRS patients were not statistically different among disease severity groups based on the endoscopic polyp score. MMP-8+ neutrophils might be essential for initiating polyp formation in the paranasal sinus mucosa rather than stabilizing the NP that has already been formed via tissue remodeling processes. In the ECRS group, the percentages of MMP-8+ neutrophils in NP tended to increase with progressing olfactory dysfunction. Although this finding may suggest that MMP-8+

neutrophils are associated with ECRS progression, the relevance of neutrophils for olfactory mucosal injury<sup>23)</sup> was not clarified in the present study.

## CONCLUSIONS

Based on various histological and clinical observations, we suggest that MMP-8+ neutrophils may be involved in the progression of ECRS leading to its intractability. A significant relationship was only observed between the presence of MMP-8+ neutrophils in NPs and the CT score. MMP-8+ neutrophils might play a role in the incipient tissue remodeling of the paranasal sinus mucosa at the early stages and/or in mildly affected cases of ECRS. Further studies examining other tissues such as the olfactory or paranasal sinus mucosa would be vital to establish MMP-8+ neutrophils as a novel target for therapeutic intervention in patients with ECRS.



**Fig. 7** Olfaction recognition thresholds in the ECRS and non-ECRS groups and subgroups. The olfaction recognition thresholds are significantly elevated in the ECRS group compared to those in the non-ECRS group (\*\* $p < 0.001$ ) (a). The olfaction recognition thresholds in the ECRS group have a mildly positive correlation with the presence of MMP-8+ neutrophils in NPs ( $r = 0.321$ ) (b). “●” and solid lines, ECRS group; “○” and dotted lines, non-ECRS group. The percentages of MMP-8+ neutrophils in NPs tend to increase with progressing olfactory dysfunction in the ECRS group (c) but not in the non-ECRS group (d). MMP-8+ : metalloproteinase-8-positive; NPs : nasal polyps; ECRS : eosinophilic chronic rhinosinusitis

## Funding

The authors received no financial support for the research, authorship, and/or publication of this manuscript.

## Conflict of Interests

None declared.

**Acknowledgements.** The authors wish to thank Dr. Kazumi Akimoto for protein analysis. The work was supported by a Grant from the Dokkyo Medical University Young Investigator Award (No. 2018-13).

## REFERENCES

- 1) Fujieda S, Imoto Y, Kato Y, et al : Eosinophilic chronic rhinosinusitis. *Allergol Int* **68** : 403-412, 2019.
- 2) Tokunaga T, Sakashita M, Haruna T, et al : Novel scoring system and algorithm for classifying chronic rhinosinusitis : the JESREC study. *Allergy* **70** : 995-1003, 2015.
- 3) Nakayama T, Sugimoto N, Okada N, et al : JESREC score and mucosal eosinophilia can predict endotypes of chronic rhinosinusitis with nasal polyps. *Auris Nasus Larynx* **46** : 374-383, 2019.
- 4) Haruna S, Nakanishi M, Otori N, et al : Histopathological features of nasal polyps with asthma association : an immunohistochemical study. *Am J Rhinol* **18** : 165-172, 2004.
- 5) Ponikau JU, Sherris DA, Kephart GM, et al : Features of airway remodeling and eosinophilic inflammation in chronic rhinosinusitis : Is the histopathology similar to asthma? *J Allergy Clin Immunol* **112** : 877-882, 2003.
- 6) Katainen E, Kostamo K, Virkkula P, et al : Local and

- systemic proteolytic responses in chronic rhinosinusitis with nasal polyposis and asthma. *Int Forum Allergy Rhinol* **5** : 294-302, 2015.
- 7) Samitas K, Carter A, Kariyawasam HH, et al : Upper and lower airway remodeling mechanisms in asthma, allergic rhinitis and chronic rhinosinusitis : The one airway concept revisited. *Allergy* **73** : 993-1002, 2018.
  - 8) Van Bruaene N, Peres-Novo C, Van Crombruggen K, et al : Inflammation and remodeling patterns in early stage chronic rhinosinusitis. *Clin Exp Allergy* **42** : 883-890, 2012.
  - 9) Wang X, Zhao C, Ji W, et al : Relationship of TLR2, TLR4 and tissue remodeling in chronic rhinosinusitis. *Int J Clin Exp Pathol* **8** : 1199-1212, 2015.
  - 10) Kostamo K, Tervahartiala T, Sorsa T, et al : Metalloproteinase function in chronic rhinosinusitis with nasal polyposis. *Laryngoscope* **117** : 638-643, 2007.
  - 11) Pawankar R, Nonaka M : Inflammatory mechanisms and remodeling in chronic rhinosinusitis and nasal polyps. *Curr Allergy Asthma Rep* **7** : 202-208, 2007.
  - 12) Eyibilen A, Cayli S, Aladag I, et al : Distribution of matrix metalloproteinases MMP-1, MMP-2, MMP-8 and tissue inhibitor of matrix metalloproteinases-2 in nasal polyposis and chronic rhinosinusitis. *Histol Histopathol* **26** : 615-621, 2011.
  - 13) Kuhar HN, Tajudeen BA, Mahdavinia M, et al : Inflammatory infiltrate and mucosal remodeling in chronic rhinosinusitis with and without polyps : structured histopathologic analysis. *Int Forum Allergy Rhinol* **7** : 679-689, 2017.
  - 14) Nagase H, Visse R, Murphy G : Structure and function of matrix metalloproteinases and TIMPs. *Cardiovasc Res* **69** : 562-573, 2006.
  - 15) Owen CA, Hu Z, Lopez-Otin C, et al : Membrane-bound matrix metalloproteinase-8 on activated polymorphonuclear cells is a potent, tissue inhibitor of metalloproteinase-resistant collagenase and serpinase. *J Immunol* **172** : 7791-7803, 2004.
  - 16) Kikuchi S, Nagata M, Kikuchi I, et al : Association between neutrophilic and eosinophilic inflammation in patients with severe persistent asthma. *Int Arch Allergy Immunol* **137** (Suppl 1) : 7-11, 2005.
  - 17) Sampson AP : The role of eosinophils and neutrophils in inflammation. *Clin Exp Allergy* **30** (Suppl 1) : 22-27, 2000.
  - 18) Tecimer SH, Kasapoglu F, Demir UL, et al : Correlation between clinical findings and eosinophil/neutrophil ratio in patients with nasal polyps. *Eur Arch Otorhinolaryngol* **272** : 915-921, 2015.
  - 19) Brescia G, Barion U, Zanotti C, et al : Pre- and post-operative blood neutrophil-to-lymphocyte and eosinophil-to-lymphocyte ratios in patients with sinonasal polyps : A preliminary investigation. *Allergy Asthma Proc* **38** : e64-e69, 2017.
  - 20) Chua F, Laurent GJ : Neutrophil elastase. Mediator of extracellular matrix destruction and accumulation. *Proc Am Thorac Soc* **3** : 424-427, 2006.
  - 21) Tsetsos N, Goudakos JK, Daskalakis D, et al : Monoclonal antibodies for the treatment of chronic rhinosinusitis with nasal polyposis : a systemic review. *Rhinology* **56** : 11-21, 2018.
  - 22) Lund VJ, Mackay IS : Staging in rhinosinusitis. *Rhinology* **31** : 183-184, 1993.
  - 23) Kashiwagi T, Tsunemi Y, Akutsu M, et al : Postoperative evaluation of olfactory dysfunction in eosinophilic chronic rhinosinusitis - comparison of histopathological and clinical findings. *Acta Otolaryngol* **139** : 881-889, 2019.
  - 24) Prikk K, Maisi P, Pirilä E, et al : Airway obstruction correlates with collagenase-2 (MMP-8) expression and activation in bronchial asthma. *Lab Invest* **82** : 1535-1545, 2002.
  - 25) Kikuchi I, Kikuchi S, Kobayashi T, et al : Eosinophil trans-basement membrane migration induced by interleukin-8 and neutrophils. *Am J Respir Cell Mol Biol* **34** : 760-765, 2006.
  - 26) Kostamo K, Sorsa T, Leino M, et al : *In vivo* relationship between collagenase-2 and interleukin-8 but not tumour necrosis factor- $\alpha$  in chronic rhinosinusitis with nasal polyposis. *Allergy* **60** : 1275-1279, 2005.
  - 27) Nadif R, Siroux V, Boudier A, et al : Blood granulocyte patterns as predictors of asthma phenotypes in adults from the EGEA study. *Eur Respir J* **48** : 1040-1051, 2016.
  - 28) Malinsky RR, Valera FCP, Cavallari FE, et al : Matrix metalloproteinases and their impact on sinus extension in chronic rhinosinusitis with nasal polyps. *Eur Arch Otorhinolaryngol* **270** : 1345-1348, 2013.