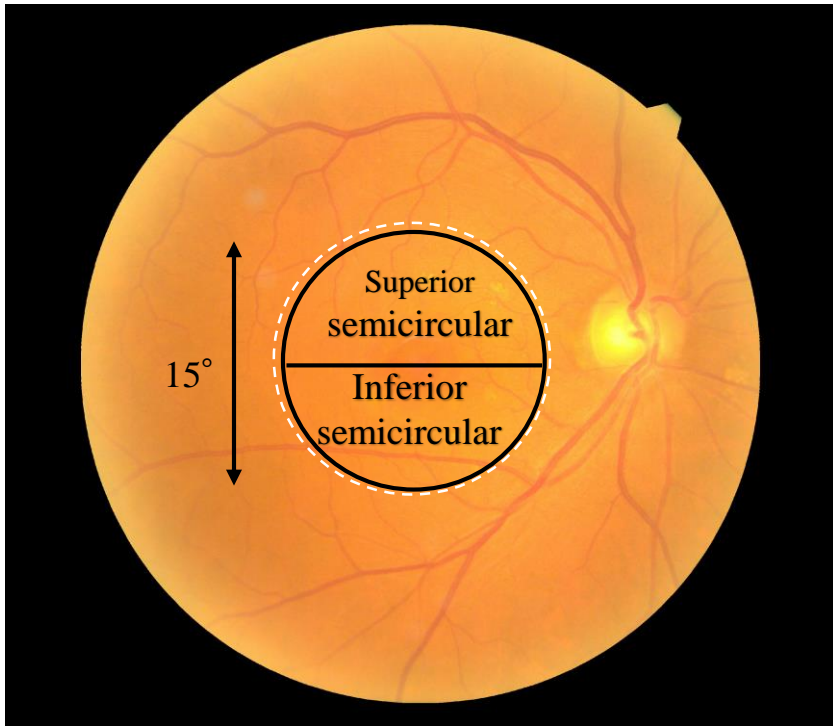
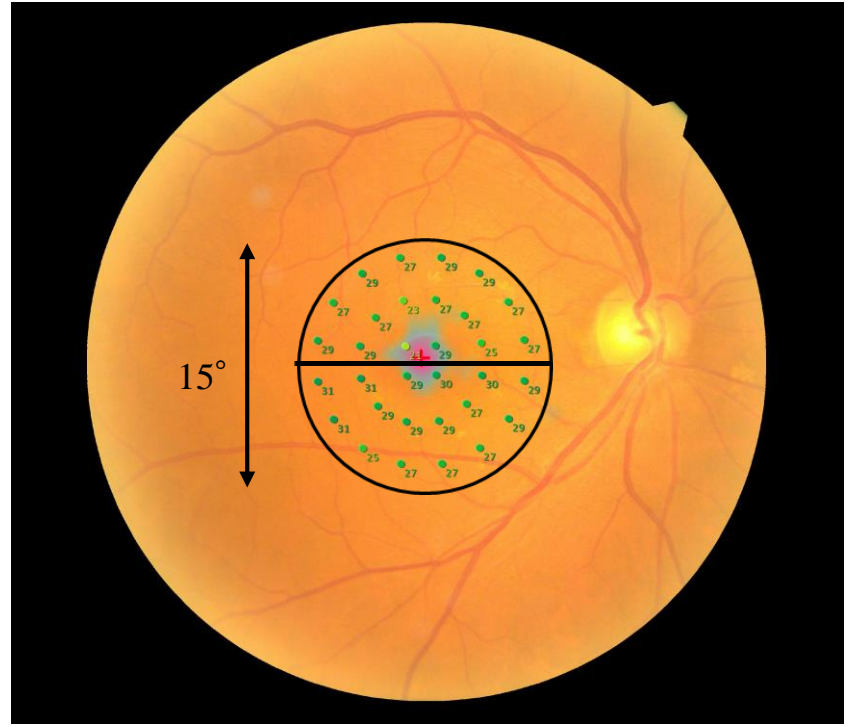


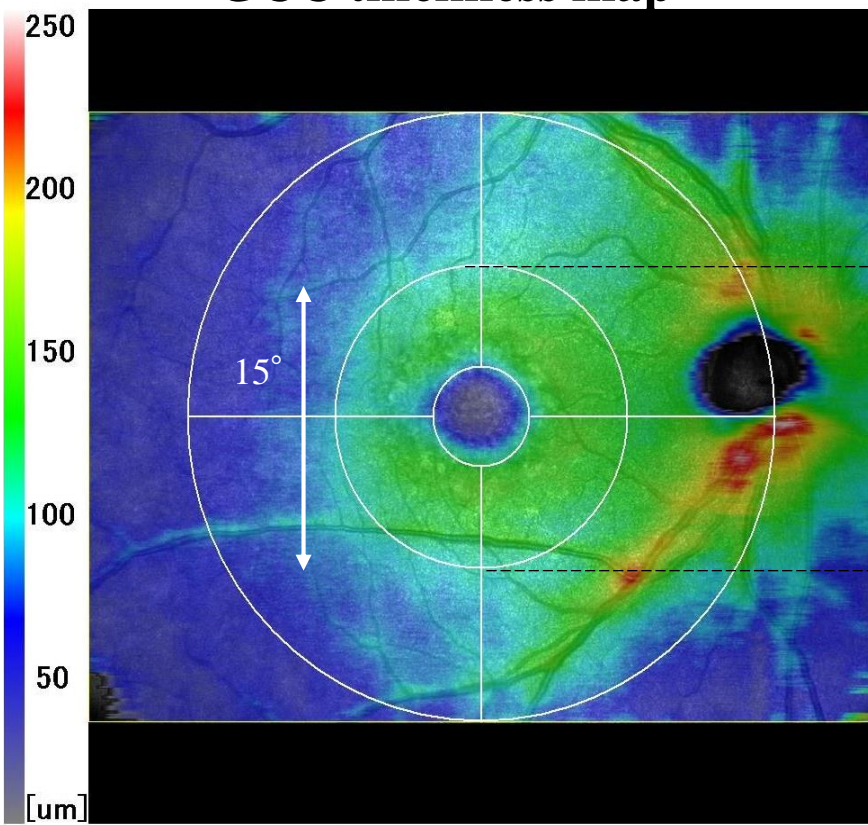
**a Focal macular ERG**



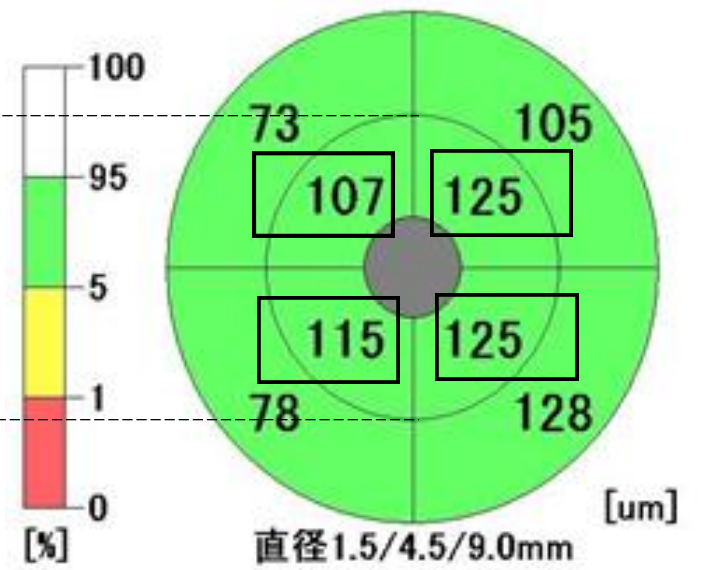
**b MP-3**



**c GCC thickness map**

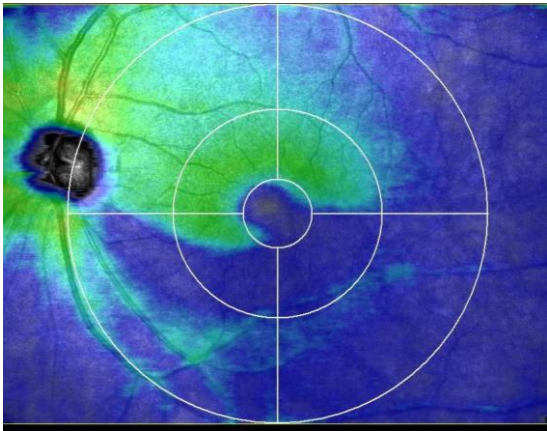


**d GCC chart**

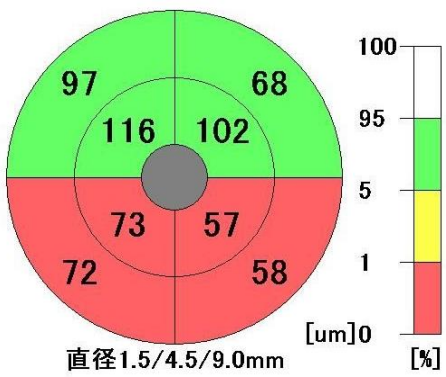


a

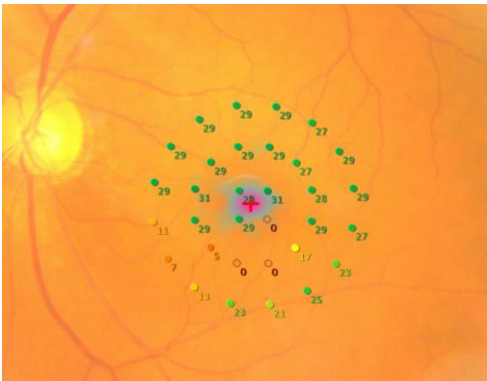
### GCC thickness map



### GCC chart

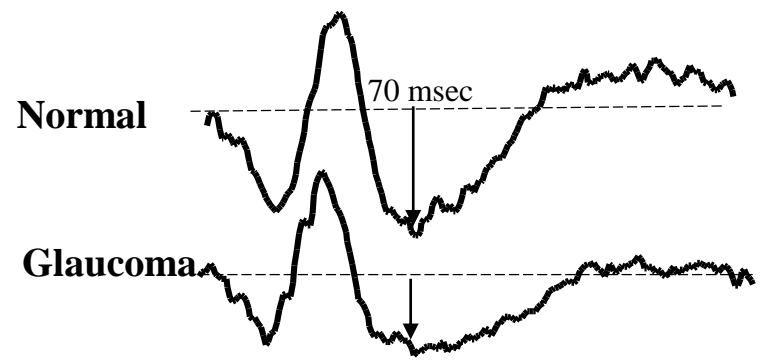


### MP-3

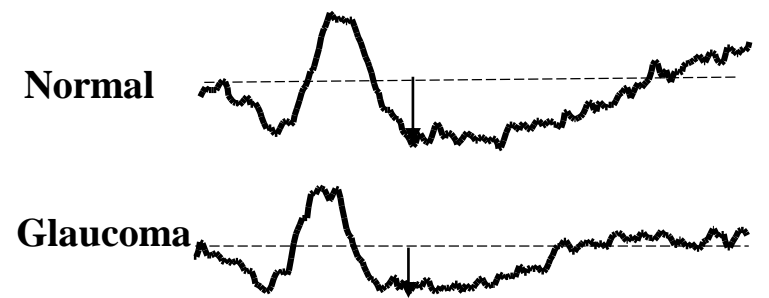


b

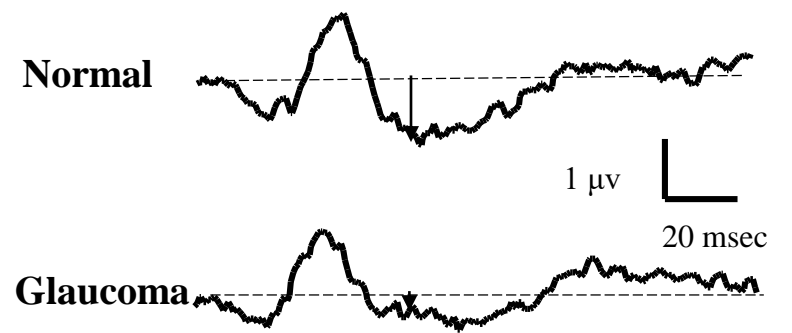
### Circle



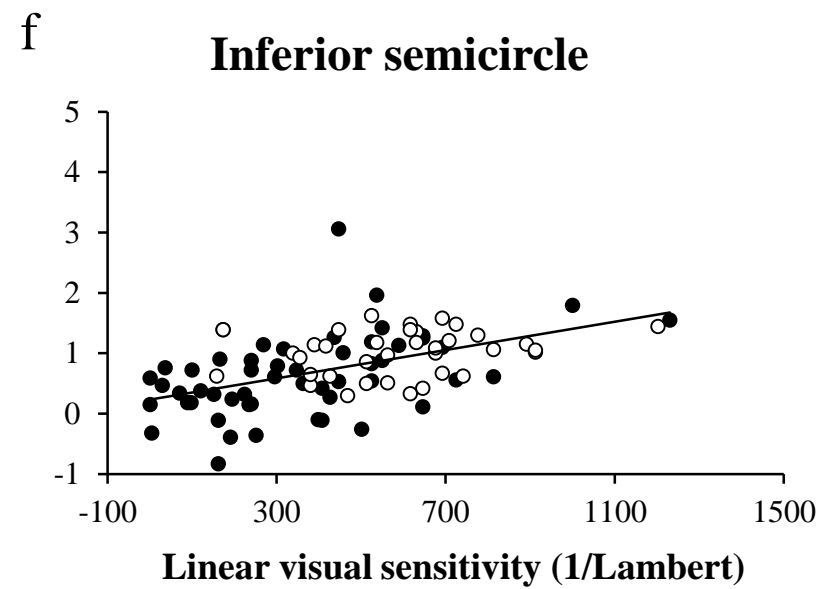
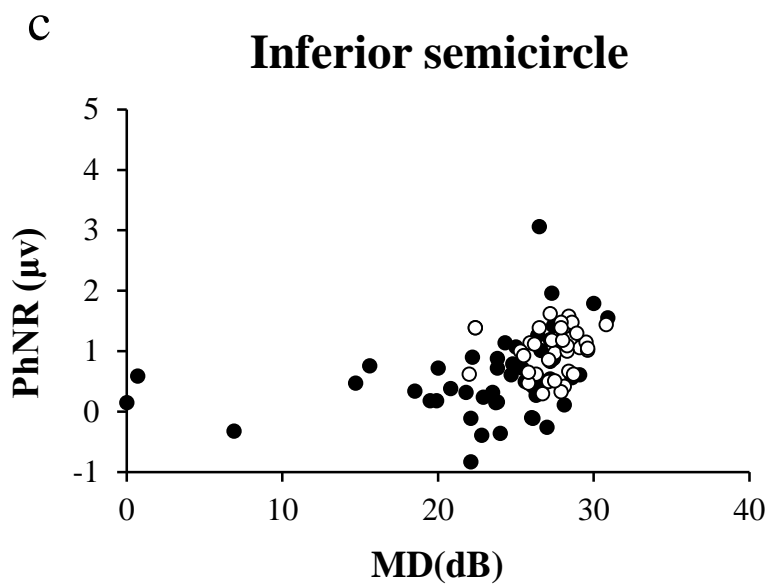
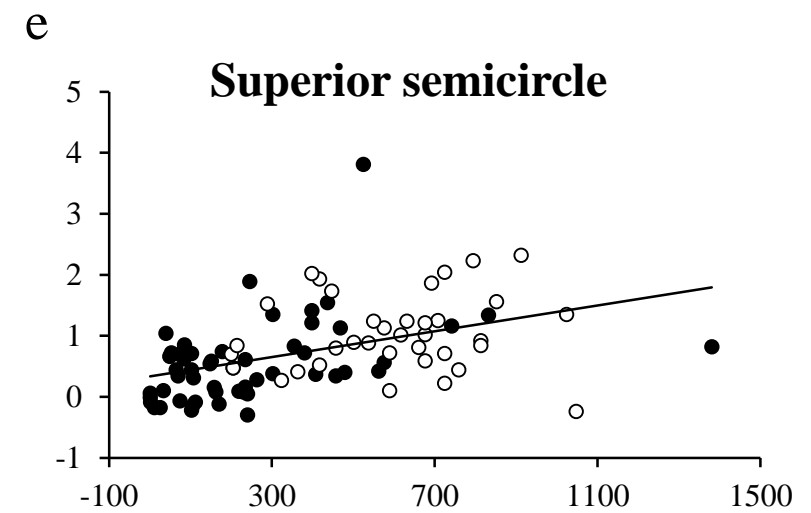
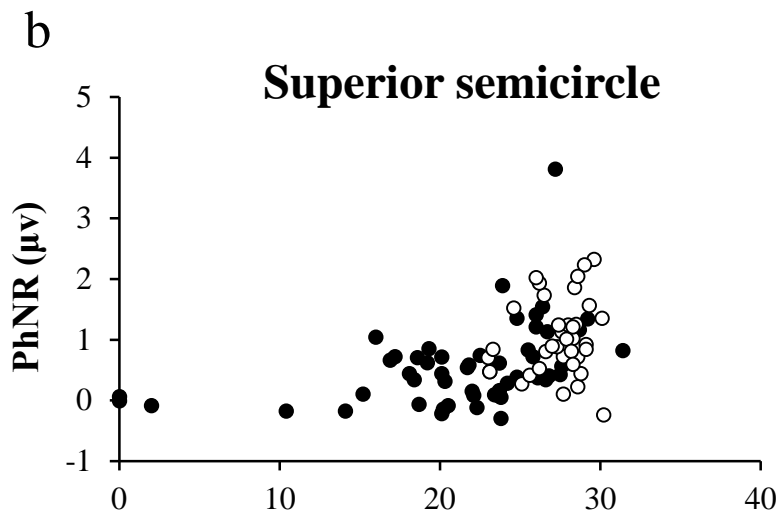
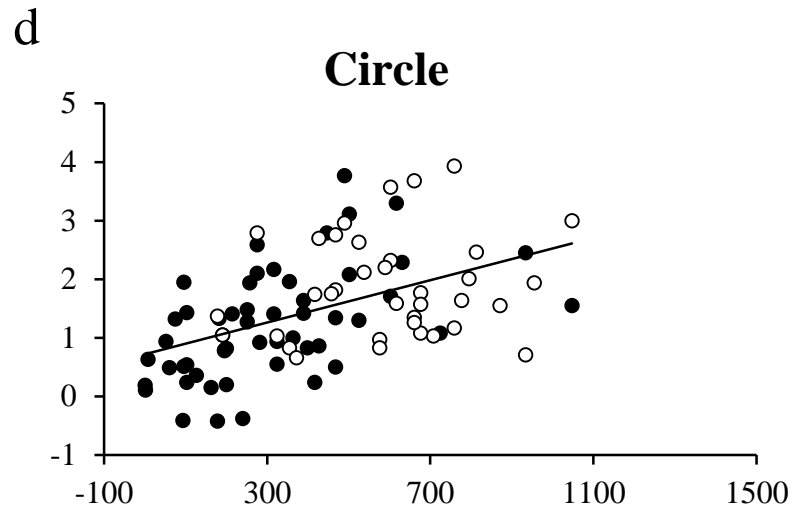
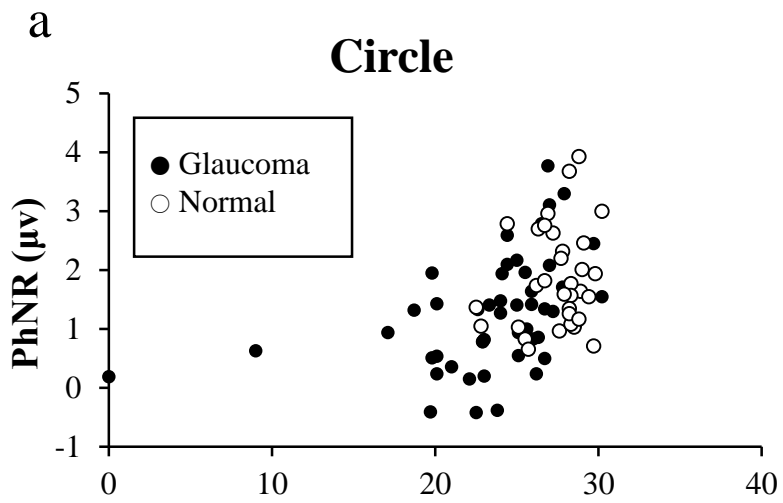
### Superior semicircle

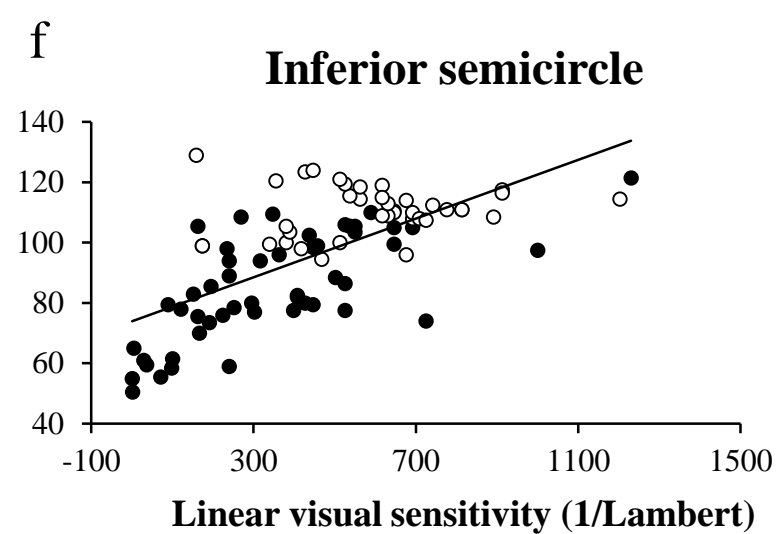
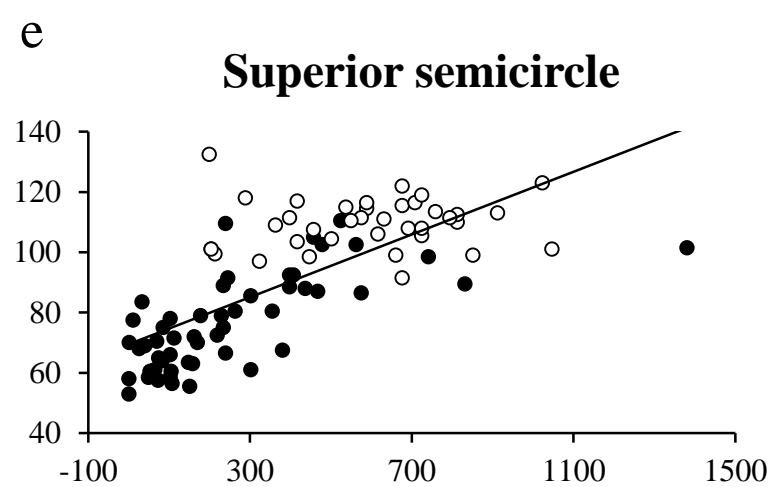
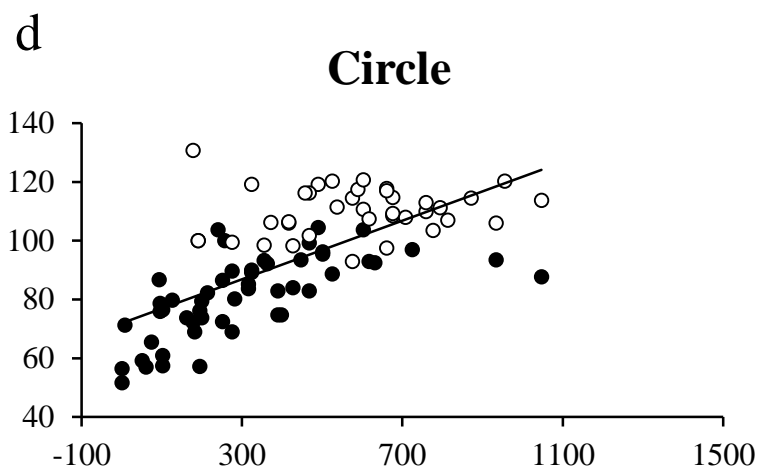
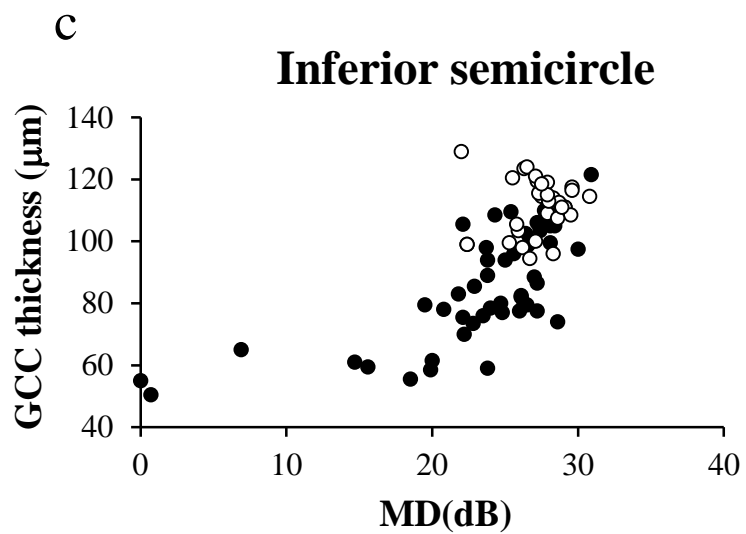
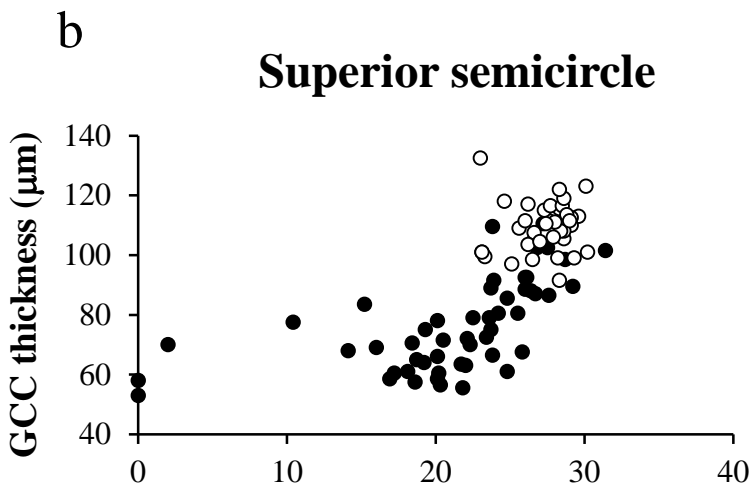
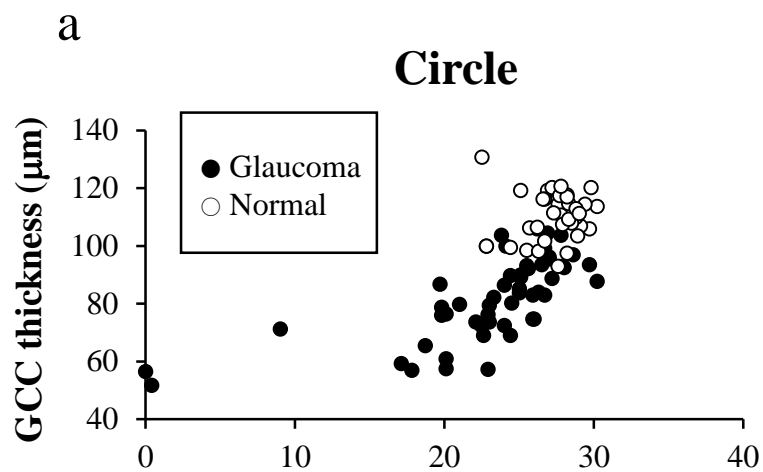


### Inferior semicircle

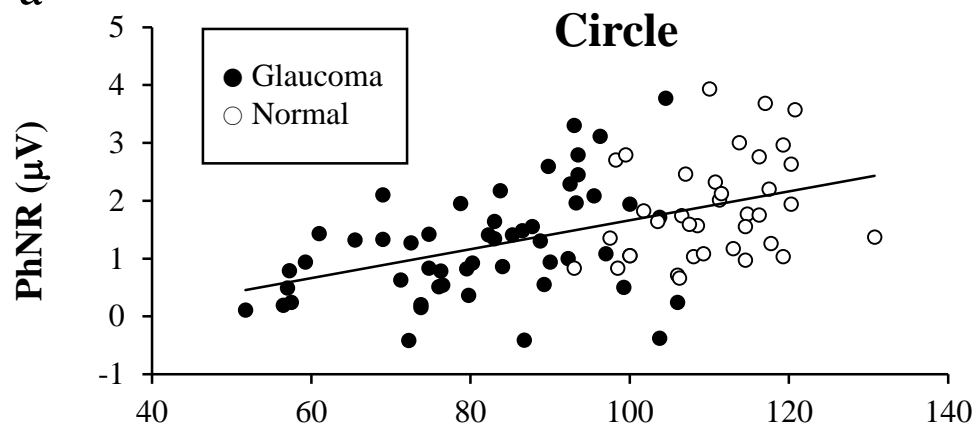


Stim.

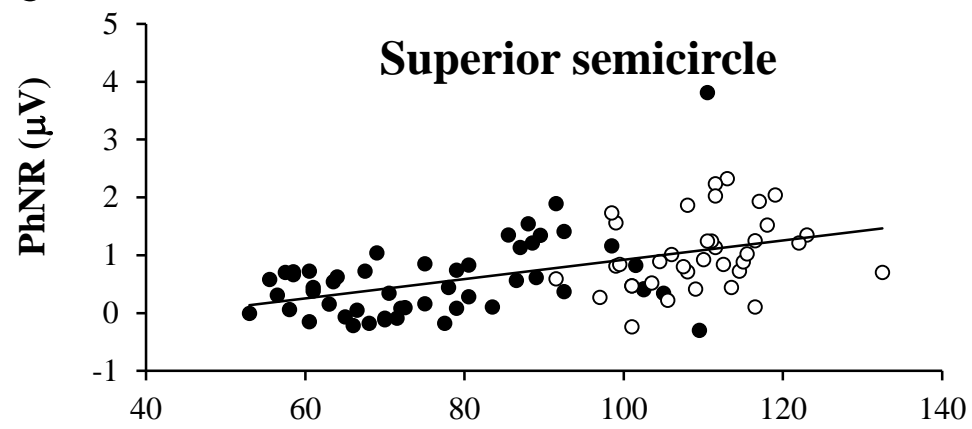




a



b



c

