

Case Report

Massive Desmoid with Keloid of the Anterior Neck

Kazufumi Sano, M.D.¹⁾, Kazuhiko Yokoshima, M.D.²⁾, Munenaga Nakamizo, M.D.²⁾,
Satoru Ozeki, M.D.¹⁾, and Kazumasa Kimura, M.D.¹⁾

¹⁾ *Department of Orthopaedic Surgery Dokkyo Medical University Koshigaya Hospital
Koshigaya Saitama, 343-8555, JAPAN*

²⁾ *Department of Otolaryngology Nippon Medical School Hospital Bunkyo Tokyo, 113-8603, JAPAN*

SUMMARY

It is a case report of a massive recurrent desmoid and overlying keloid that simultaneously occurred in the anterior neck. A 21-year woman presented with a 4-year history of a recurrent desmoid with a keloid of the skin in the anterior neck. The desmoid and overlying keloid were excised en-bloc with episternotomy. The defect was covered with the rotated pectoralis major muscle flap, and then resected episternum was returned after inactivation by liquid nitrogen. Skin defect of the anterior neck was covered with the free radial forearm flap. Although there is no evidence of recurrence of the desmoid a year later, recurrence of the keloids is remarkable. As to our knowledge, it is rare that desmoids and keloids occur simultaneously. It might be an opportunity to explain a strange character of desmoids based on clinical nature of keloids.

Key Words : desmoid, keloid, hypertrophic scar, radial forearm flap, head and neck

INTRODUCTION

Both desmoids and keloids of the skin are benign mesenchymal tumor originating fibroblasts and including abundant collagen, and typically have an infiltrating border¹⁾. Although there is a common histopathological feature between desmoids and keloids, each tumor is usually treated separately. In this case, a keloid formation appeared in a massive desmoid in the anterior neck region. The course of this case indicates the existence of enigma as to the etiology of keloid-type recurrence of desmoid tumor.

The procedures were followed in accordance with the ethical standards of the committee on human ex-

perimentation of our institution.

CASE REPORT

A 21-year woman presented with a 4-year history of a recurrent desmoid with a keloid of the skin in the anterior neck (Figure 1A). She did not have a keloid in other body areas. She underwent tumor excision three times until then. At the first time, a subcutaneous mass sized 1×2 cm at the upper anterior chest wall was resected and pathologically diagnosed as a desmoid. The tumor recurred with more rapid and massive appearance with keloid formation of the operative wound every after each resection. The sagittal view of MRI demonstrated a desmoid deeply extended to the upper anterior mediastinum (Figure 1B). Further excision of keloids on the skin and episternotomy were planned. An 18×8.5×14 cm sized tumor including the overlying keloid and episternum were resected en-bloc with marginal margin (Figure 2A, B). The exposed brachicephalic trunk was covered with the rotated pectoralis major muscle flap (Figure 2C), and

Received April 21, 2009 ; accepted July 7, 2009

Reprint requests to : Kazufumi Sano, MD.

Department of Orthopaedic Surgery Dokkyo
Medical University Koshigaya Hospital 2-1-
50 Minami-koshigaya Koshigaya Saitama,
343-8555 Japan.

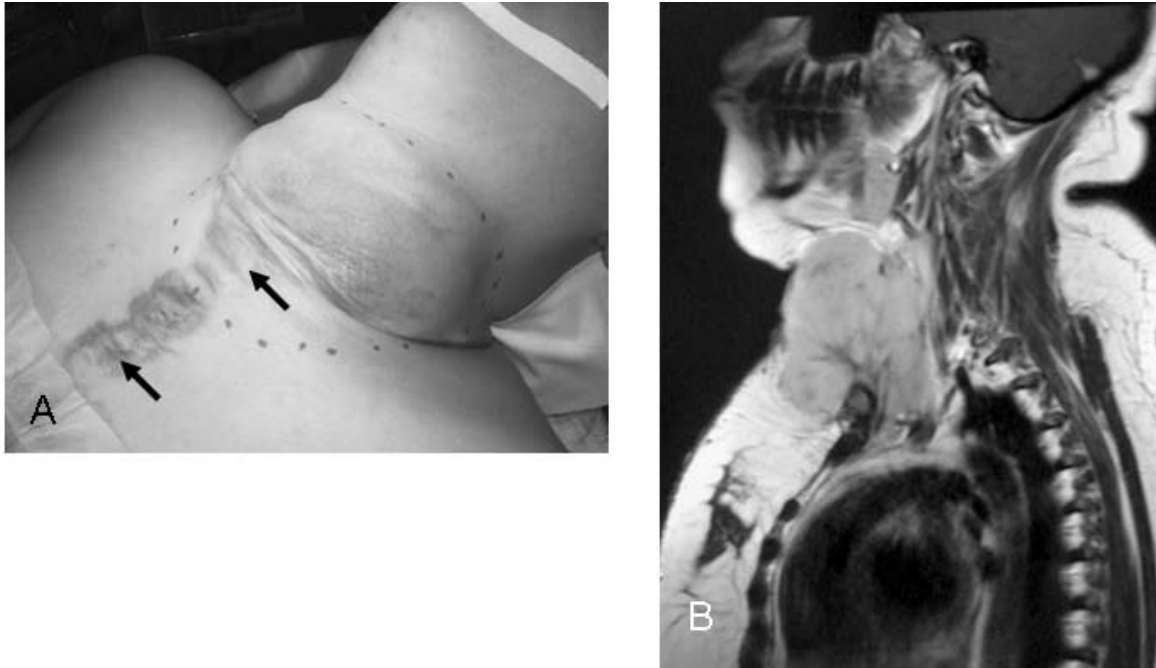


Figure 1

- A** : Recurrent desmoid tumor, that adhered to overlying skin, aggressively grew in the supraclavicular region. Keloid formation was also identified in the upper-chest scars of the past operations. Areas of Black arrows, at which there were no postoperative scar originally, indicate longitudinal growing region of the keloid.
- B** : Sagittal view of MRI demonstrated a desmoid deeply extended to the upper anterior mediastinum.

then resected episternum was returned after inactivation by liquid nitrogen (Figure 2D). Skin defect of the anterior neck was covered with the free radial forearm flap (Figure 2E, F). The patient refused our proposal of postoperative radiotherapy for prevention of further recurrence. Although there was no evidence of recurrence of the desmoid a year later, remarkable keloid formation was observed on the operative wound (Figure 3A, B).

DISCUSSION

Since radical resection of desmoid tumors in the head and neck region are frequently inoperable to the proximity to vital structures^{2,3}, postoperative radiotherapy is recommended as an important adjunct therapy^{3,4}. To date, no significant association between positive margins and recurrence has been verified, and it also remains unclear why some tumors continue to grow while others can be followed for long periods without any adverse sequelae³. These questions can be extrapolated with relationship between “keloids” and “hypertrophic scars”. Although both skin tumors are pathologically difficult to distinguish from each other,

their clinical features are quite different. Keloids generally show aggressive growth beyond the border of the original wound. Without postoperative radiotherapy, recurrence after surgical resection irrespective of its surgical margin invariably occurs. On the other hand, hypertrophic scars also show aggressive growth but remain inside of the border of the original wound. Postoperative radiotherapy is usually unnecessary after resection, and even spontaneous remission is sometimes identified during their follow-up. Desmoids seem to appear with each of these characters, that is, “keloid type” or “hypertrophic scar type”. When recurrence occurs beyond the surgical margin, after, the desmoid tumor is defined as “keloid type”, which requires radiation therapy. If no recurrence is identified postoperatively, the tumor is thought to be “hypertrophic scar type”. Although this case was considered to be “keloid type” with consideration of the past repeated recurrences, the patient refused our proposal of adjuvant radiotherapy. There was no recurrence a year after resection, but further recurrence would not be avoided.

Recent metabolic study of keloids and hypertrophic

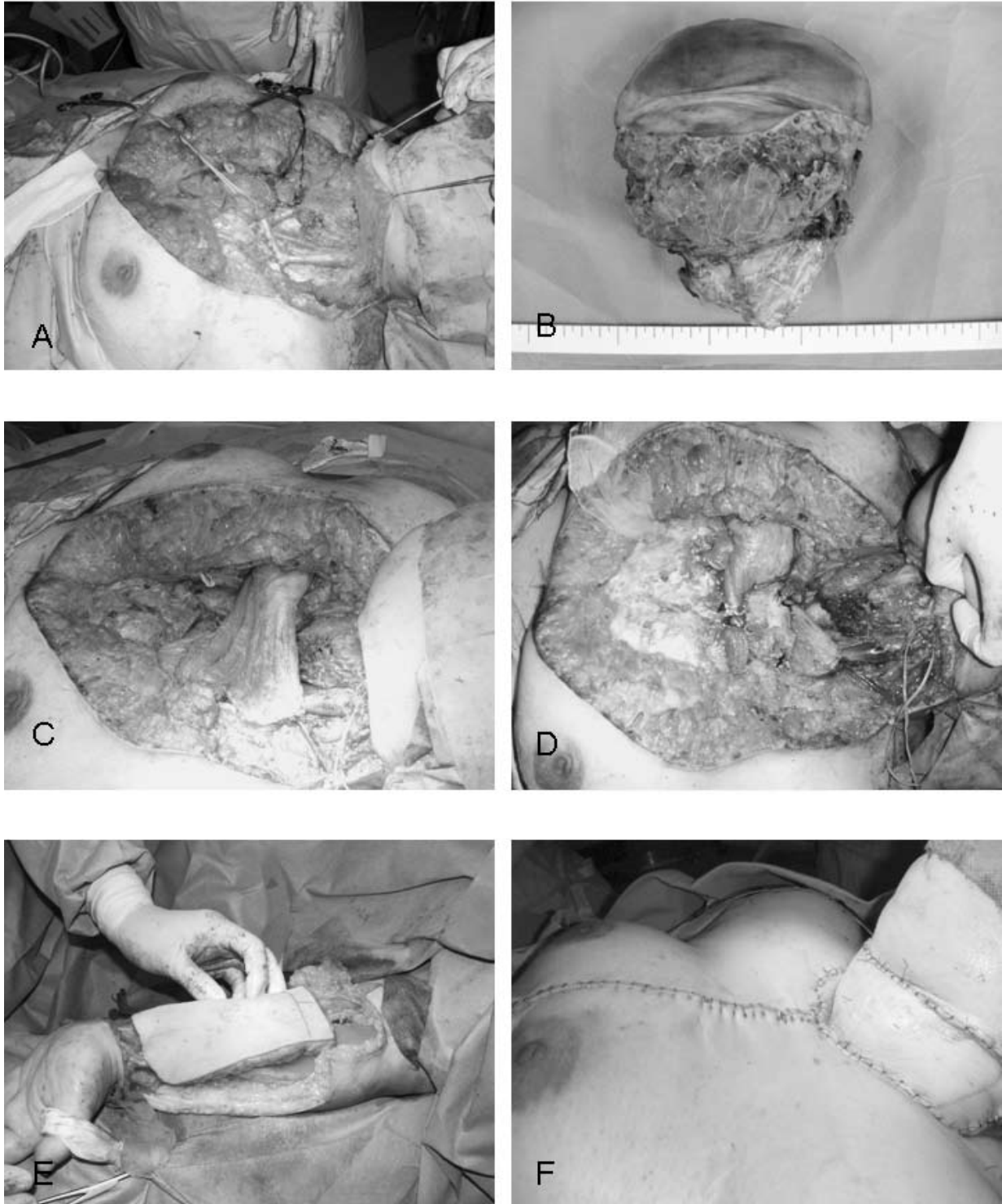


Figure 2

- A : Exposed brachicephalic trunk after desmoid resection with the overlying keloid and episternum.
 B : Resected desmoid.
 C : Brachicephalic trunk was exposed and covered with the rotated pectoralis major muscle flap.
 D : Episternum was once resected, and then returned after inactivation by liquid nitrogen.
 E : Harvest of the free radial forearm flap.
 F : Postoperative view.

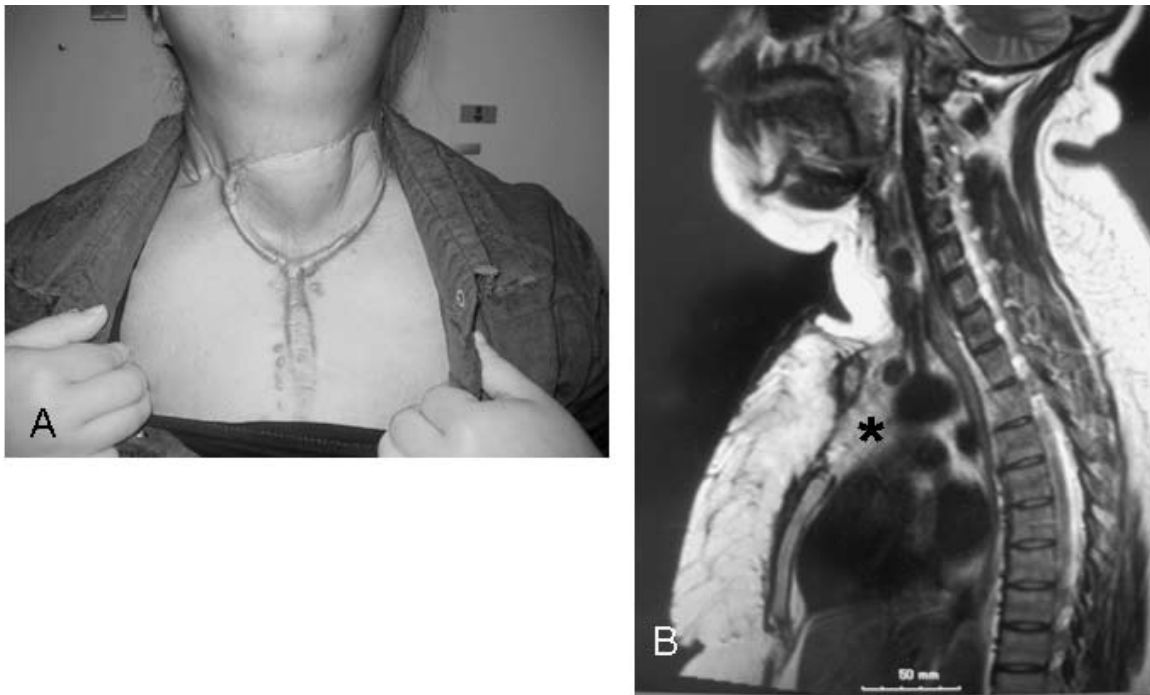


Figure 3

A year after operation,

A : Keloid formation with scar contracture is remarkable.

B : No recurrence on sagittal view of MRI. Asterisk indicates the rotated pectoralis major muscle flap.

scars using proton nuclear magnetic resonance (1HNMR) revealed that metabolite of keloid tissue includes more lactic acid, which reflects active anaerobic metabolism, than that of hypertrophic scar tissue⁵⁾. Usefulness of 1HNMR was also proved in distinguishing a malignant breast tumor from a desmoid mimicking a malignancy with detection of elevated levels of choline compound⁶⁾. Magnetic resonance spectroscopy may contribute to determining whether a desmoid is “keloid type” or “hypertrophic scar type”, and eventually helpful for decision making of adjuvant radiotherapy for desmoids.

REFERENCES

- 1) Kofoed H, Kamby C, Anagnostaki L : Aggressive fibromatosis. *Surg Gynecol Obstet* **160** : 124-127, 1985.
- 2) Hoos A, Lewis JJ, Urist MJ, et al : Desmoid tumors of the head and neck- a clinical study of a rare entity. *Head Neck* **22** : 814-821, 2000.
- 3) Merchant NB, Lewis JJ, Woodruff JM, et al : Extremity and trunk desmoid tumors. *Cancer* **86** : 2045-2052, 1999.
- 4) Anderson T, Weinstein GS, Harwick J, et al : Hypopharyngeal desmoid tumor. *Otolaryngol Head Neck Surg* **123** : 279-281, 2000.
- 5) Iwakiri I, Wang CM, Hyakusoku H, et al : A metabolic study of keloids and hypertrophic scars using ‘1’ H-NMR. *J Jpn Soc Plast Reconstr Surg* **21** : 472-480, 2001.
- 6) Okamoto K, Kurihara Y, Imamura K, et al : Desmoid tumor of the breast : the role of proton magnetic resonance spectroscopy for a benign breast lesion mimicking a malignancy. *Breast J* **14** : 376-378, 2008.